

Renal Study Day Case Presentation

Dr. Aoife Owens ST2

November 2018



Background

- Mum – 17yrs old
 - Normally fit and well
 - O negative
 - Non-smoker
 - Unemployed
- Dad – 17yrs old
 - Normally fit and well
 - Unemployed
- Parents no longer together



Pregnancy

- Received antenatal care
 - Uncomplicated pregnancy
- EDD: 28/12/2017
- Serology: negative
- USS normal



Labour

- Presented in spontaneous preterm labour at 32 + 4 weeks
- Incomplete course of steroids
 - 1st dose given 5hrs prior to delivery
- ROM – 7hrs prior to delivery
- SVD of life female infant at 13:21 pm
- Bwt: 1.82kg (50th centile)
- Cephalic presentation



Resuscitation

- Born in good condition
 - Cried immediately
 - HR > 100bpm throughout
- Given nasal CPAP on resuscitaire
 - Maximum $f_{iO_2} = 50\%$
 - Titrated quickly to air
- Transferred to the NNU on CPAP in air
- APGAR: 9 at 1min, 10 at 5min and 10 at 10min



Stay on NNU

- Respiratory
 - Weaned quickly to high flow
 - Intermittent periods of respiratory support throughout admission
- Cardiovascular
 - Haemodynamically stable throughout
- Neurology
 - CrUSS normal, appropriate tone and movement



Stay on NNU

- Hepatic
 - 5 days of phototherapy
- Infection
 - No antibiotics after birth
 - 48hrs of abx on day 9 for suspected long line sepsis
- Feeds
 - Maternal EBM and Fortifier



Stay on NNU

- Renal
 - Albumin of 25 on day 1
 - Albumin noted to steadily decline; 10 on day 10 of life
 - Clinically oedematous; pitting oedema to legs and ascites
 - Urine dip; protein +++++ (but variable at times)
 - Protein:Creatinine elevated
 - > 9000mg/mmol



- Discussions with renal team in UHW
? Congenital Nephrotic Syndrome

Congenital Nephrotic Syndrome

- Combination of:
 - Heavy proteinuria (urinary protein:creatinine $>200\text{mg}/\text{mmol}$)
 - Hypoalbuminaemia (albumin $<25\text{g}/\text{L}$)
 - Oedema
 - Hyperlipidaemia

Occurring either at birth or within the first 3 months of life



Congenital Nephrotic Syndrome

- Aetiology
 - Genetic
 - NPHS1 – Finnish Type
 - NPSH2
 - NPSH3 (PLCE1)
 - WT1
 - LAMB2
 - Idiopathic



Congenital Nephrotic Syndrome

- NPHS1 – Finnish Type
 - Autosomal recessive inheritance
 - Increased AFP antenatally
 - Commonly born premature
 - Low birth weight
 - Enlarged placenta
 - Widespread sutures, flexion deformities of hips and knees
 - Oedema presents early
 - Profound hypoalbuminaemia



Congenital Nephrotic Syndrome

- NPHS2
 - Autosomal recessive
 - Raised AFP
 - Normal birth weight
 - Normal placenta
 - Nystagmus
 - Cataracts
 - Intellectual disability
 - Microcephaly



Congenital Nephrotic Syndrome

- Non-genetic causes
 - Infections
 - Congenital syphilis
 - Congenital toxoplasmosis
 - CMV
 - Rubella
 - HIV
 - Mercury exposure
 - SLE



Detailed history

- No Finnish, Irish or other European Ancestry
- No family history of renal problems
- No maternal or family history of SLE
- Maternal grandfather HSP and ITP in first 2 decades of life
- Mum didn't eat lots of oily fish
- No comment on placental size, no placental weight post-natally



Maternal Investigations

- Serology repeated
 - AFP – 76KU/l ↑
 - Rubella – immune
 - Hep B – negative
 - HIV – negative
 - Syphilis - negative
 - Toxoplasma – negative
 - CMV - negative
- Anti-Ro and Anti-La antibodies; negative



Patient Investigations

- Genetics NPHS1, NPHS2, WTI, LamB2, PLCE1, LMX1B
- Ophthalmology; NAD but will follow up
- Urine CMV - negative
- USS – normal liver, spleen and gallbladder with echogenic kidneys and loss of normal differentiation
- TFTs; TSH 23.5 – 11.6, Free T4 12.6 – 9.8



Genetics

Congenital Nephrotic Syndrome

NPHS 1 gene positive; Finnish variant

Congenital Nephrotic Syndrome

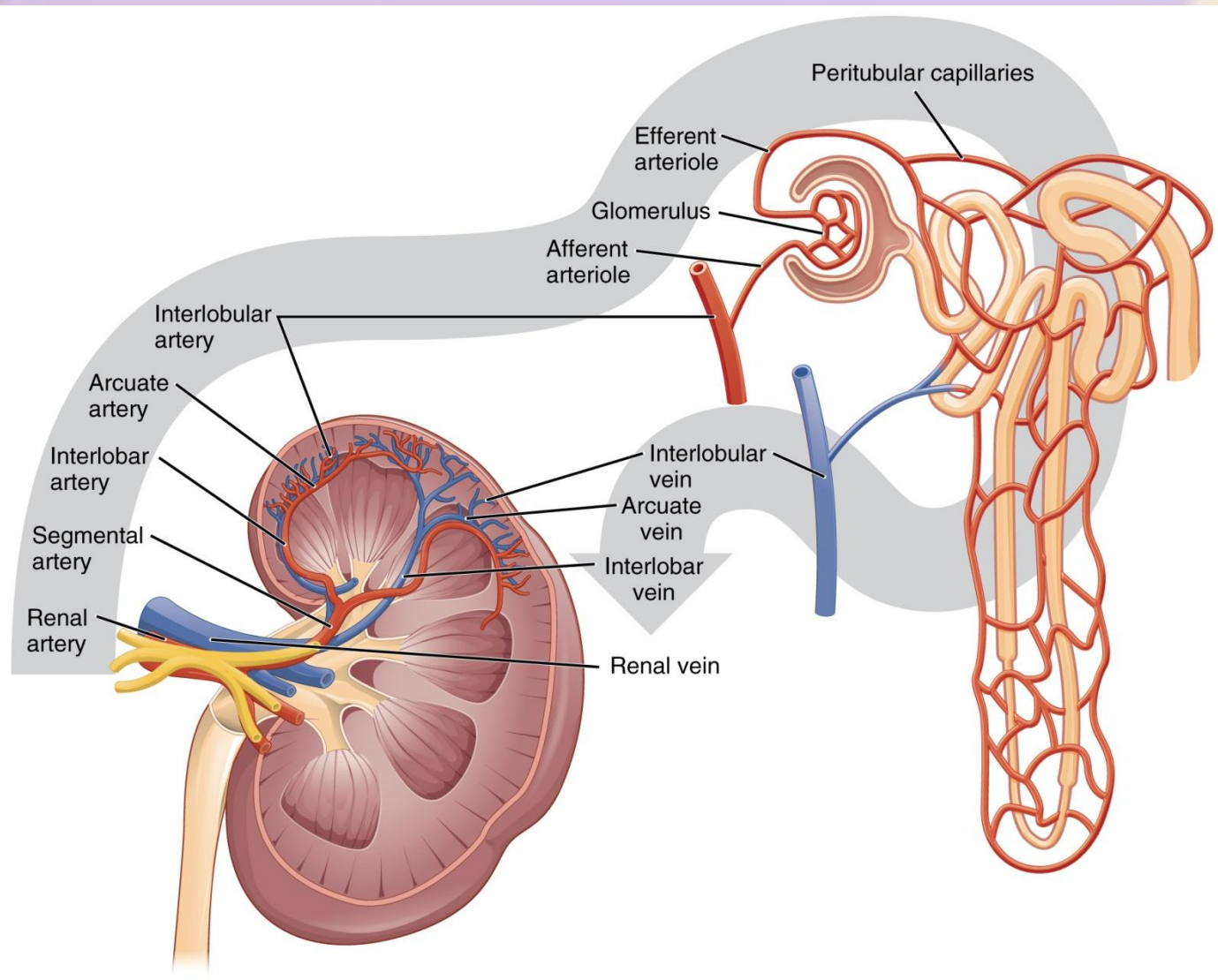
– *Finnish Type*

- Occurs in 1 per 10,000 births in Finland
- Autosomal recessive
 - Heterozygous individuals asymptomatic
- Both sexes equally affected
- NPHS1 encodes for a transmembrane protein; nephrin.



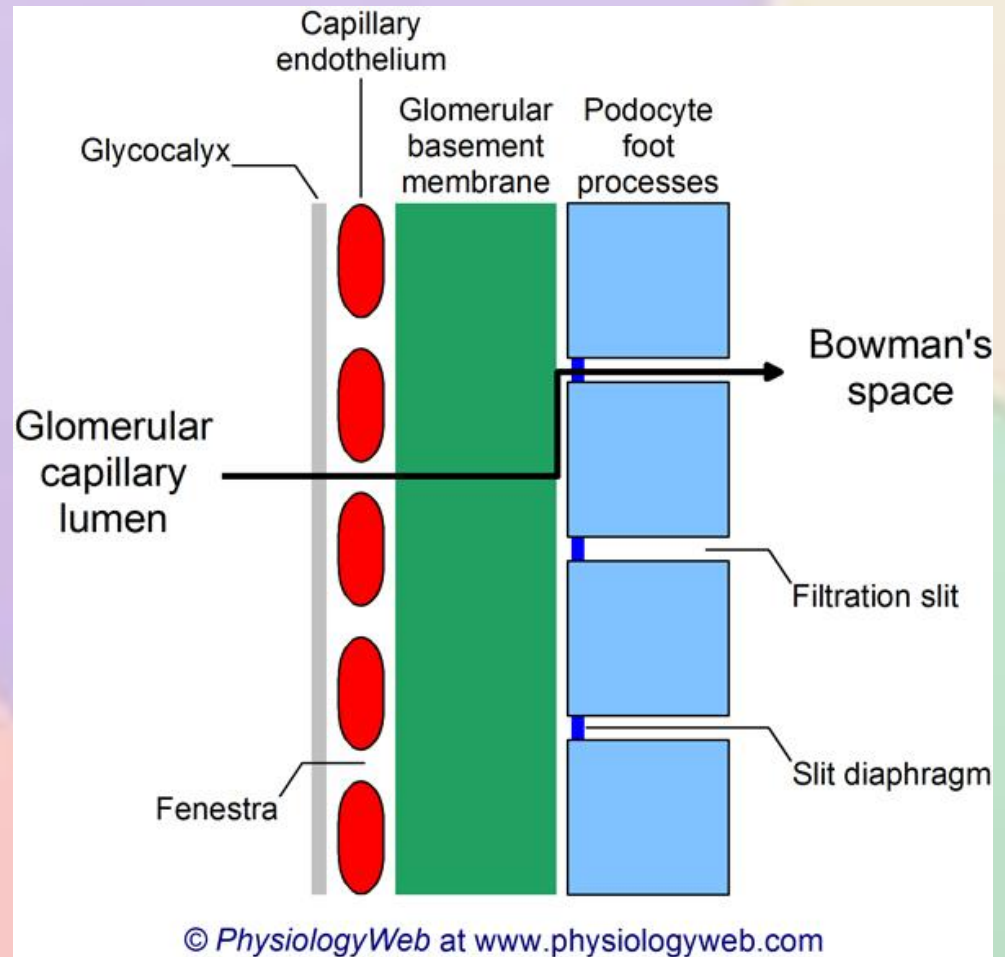
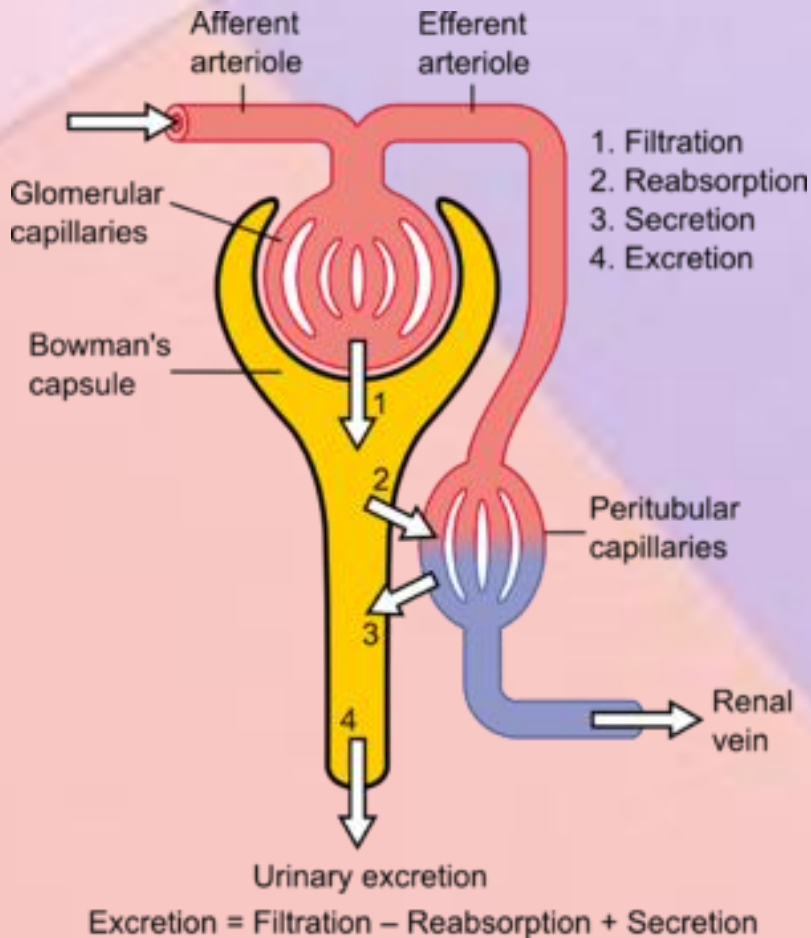
Congenital Nephrotic Syndrome

– *Finnish Type*



Congenital Nephrotic Syndrome

– *Finnish Type*



Congenital Nephrotic Syndrome

– *Finnish Type*

Signs and symptoms

- Early onset oedema
- Marked ascites
- Hypoalbuminaemia and hypogammaglobulinemia
- Poor growth
- Hypercoaguable



Congenital Nephrotic Syndrome

– *Finnish Type*

- Hyperlipidaemia
- Hypothyroidism
- Renal USS - enlarged, hyperechogenic kidneys without normal corticomedullary differentiation.
- Biopsy - loss of corticomedullary differentiation, and the diagnosis is confirmed by renal biopsy showing the characteristic irregular dilatation of proximal convoluted tubules
- End-stage renal disease usually occurs between three and eight years



Congenital Nephrotic Syndrome

- Treatment

- Resistant to steroids and immunotherapy, non-immunologic disease
- Regular albumin infusions
- Nutrition support; high protein, low-salt diet
- Vitamin replacement
- Thyroxine substitution



Congenital Nephrotic Syndrome

- Treatment
 - Prevention of infection
 - Thrombotic complications
 - Combination of ACE- inhibitors and indomethacin therapy
 - Nephrectomy
 - Renal transplant



Diagnosis

- Congenital Nephrotic Syndrome
- Ex-Preterm 32+5
- Hypothyroidism
- Vitamin D deficiency
- Zinc deficiency
- Hypertriglyceridaemia




Management

- Management of acute infections
 - Prolonged PICU admission
- Medical management to reduce proteinuria
- Optimising nutrition
- Regular HAS infusions
 - Initially several times per week
 - At present trial of 3 weekly HAS infusions
- Ultimately will need a renal transplan
- Future pregnancies





Questions



©2016 The Awkward Yeti

