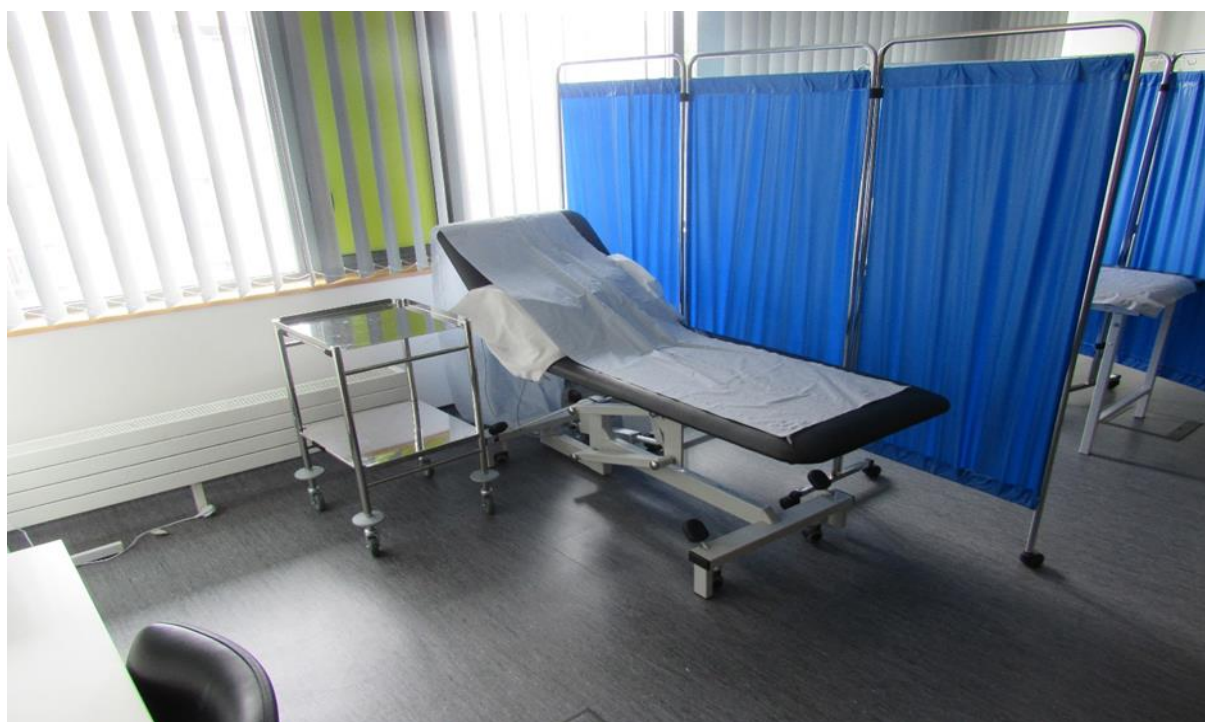

# **An Illustrated Guide For Cardiovascular System Examination**

**Bedside Teaching for 2<sup>nd</sup> year medical Students**



**Prepared by:**

**Dr. Farid Ghalli**

**Clinical Teacher (Hon)**

**2016**

# Cardiovascular System Examination

## Inspection

- Shape of precordium
  - Apex beat
- Pulsation in other areas
  - a. Pulmonary
  - b. Parasternal
  - c. Aortic
  - d. Neck
  - e. Epigastric
  - f. JVP

## Palpation

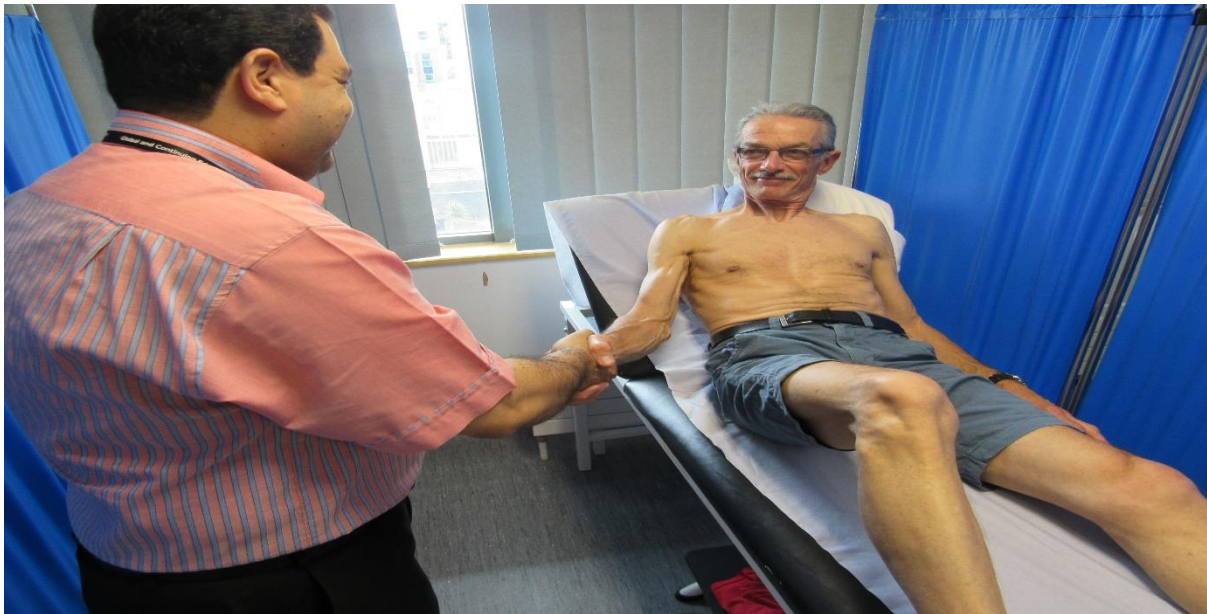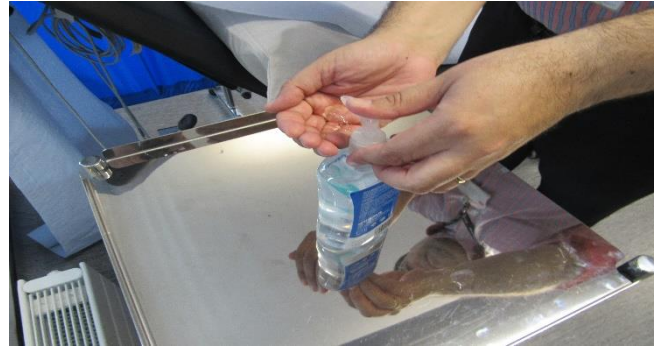- i. Apex beat localization
- ii. Pulsation in following areas
  - Pulmonary
  - Parasternal
    - Aortic
  - iii. Thrills:
    - Mitral
    - Aortic
- Carotid artery
- Pulmonary
- Parasternal
- iv. Palpates liver for hepatojugular reflux,
- v. Feels for pulsatile liver
- vi. Palpates for oedema.

## Auscultation

- i. Heart sounds:
  - Mitral area M
  - Pulmonary area P
  - Aortic area A
  - Tricuspid area T
  - Opening snap
- ii. Murmurs:
  - Mitral area
  - Aortic area
- Bruit over carotids
- Pulmonary area
- Tricuspid area
- Parasternal area
- iii. Pericardial rub
- iv. Listening to the base of lungs.

### Before Examination :

- Wash hands
- Introduce yourself
- Confirm patient details – *name / DOB*
- Explain the examination
- Gain consent
- Expose the patient's chest
- Position patient at 45°
- Ask patient if they have pain anywhere before you begin!



## General Examination

- ☑ **Appearance** : Looks Well/Ill , Consciousness , Alert .
- ☑ **Body Built** : Average , Thin , Obese ( Depends On BMI ) .
- ☑ **Color** : Pale , Cyanosed .
- ☑ **Decubitus** : Patient's position in bed .
- ☑ **Distress** : Difficulty In Breathing ( Dyspnoeic ) .
- ☑ **Any surrounding Clues** : IV Line , Catheter , O<sub>2</sub> Mask , ECG , Wheelchair , ...etc.

### Vital Signs

#### Pulse :

- 1- Radial Artery .
- 2- Brachial Artery .

### 3- Carotid Artery :

- This Is The Best Place To Assess The Pulse Volume And Character .
- Be Careful Not To Compress Both Carotids At Once , For Fear Of Diminishing Blood Flow To The Brain .

### 4- Femoral Artery :

- Can Be Felt Midway Between The Pubic Tubercle And The Anterior Superior Iliac Spine.

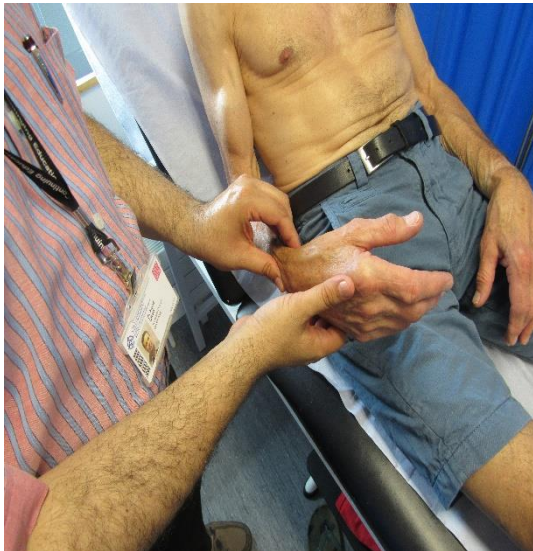### 5- Popliteal Artery .

### 6- Posterior Tibial Artery

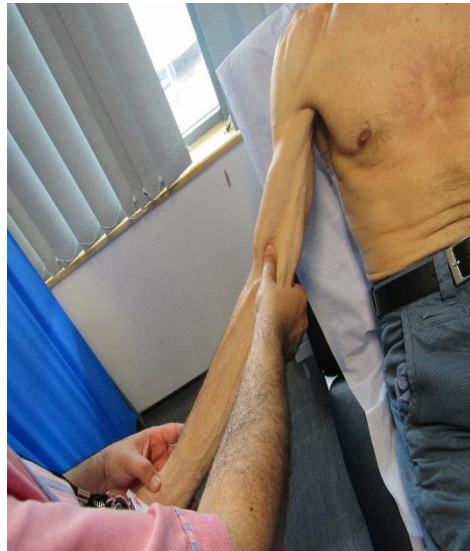- Palpate At The Ankle Just Posterior And Inferior To The Medial Malleolus

### 7- Dorsalis Pedis :

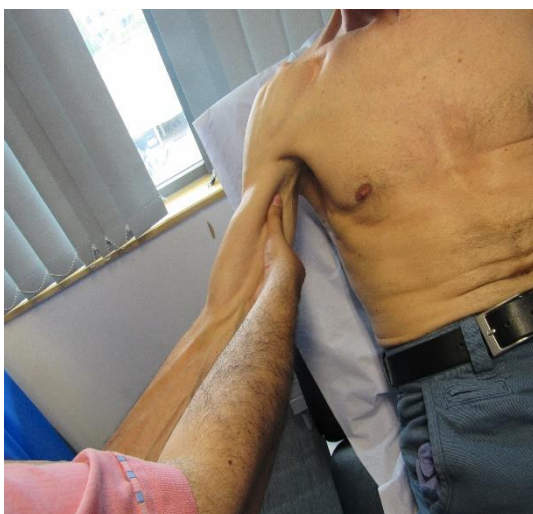
- This Runs Lateral To The Exterior Hallucis Longus Tendon On The Superior Surface Of The Foot Between The Bases Of The First And Second Metatarsals .



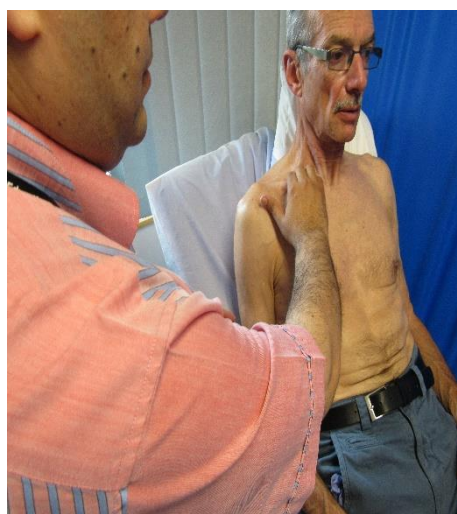
1. Radial artery



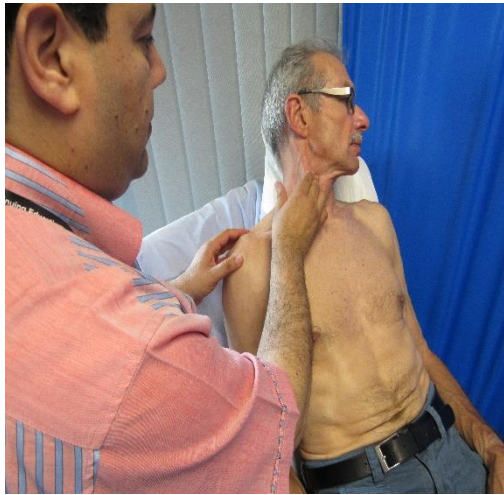2. Brachial artery



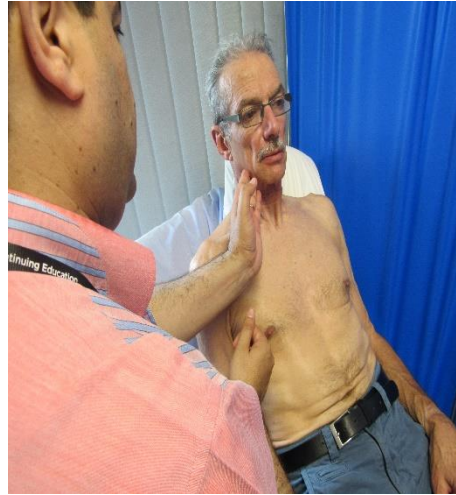3. Axillary Artery



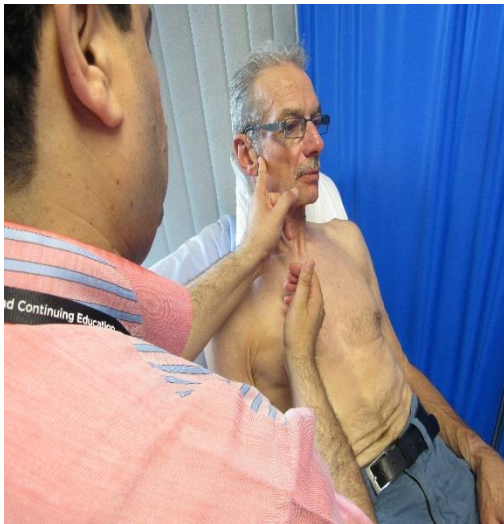4. Subclavian Artery



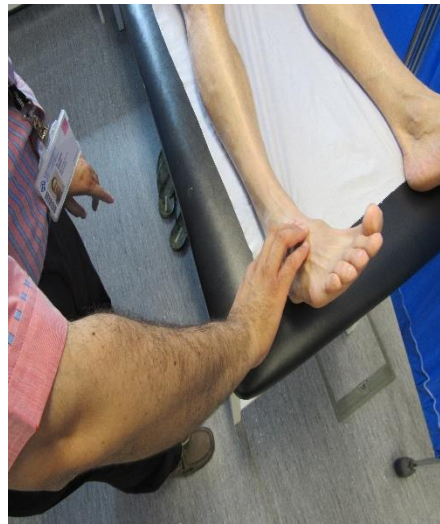**5. Carotid Artery**



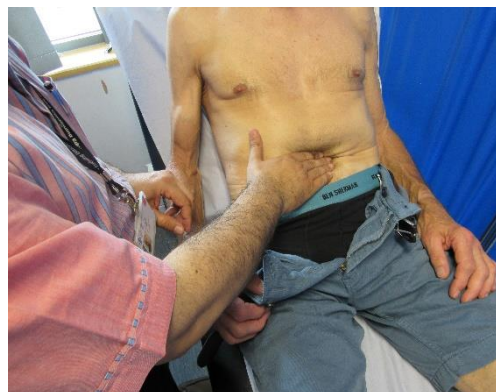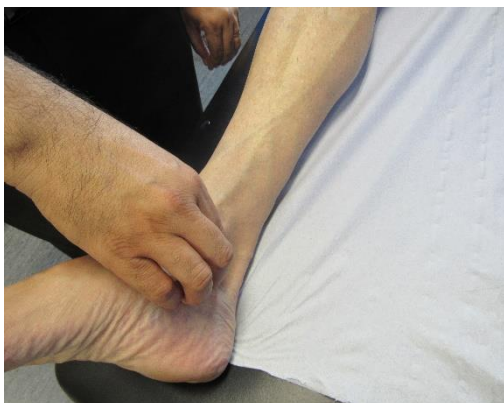**6. Facial Artery**



**7. Superficial Temporal Artery**

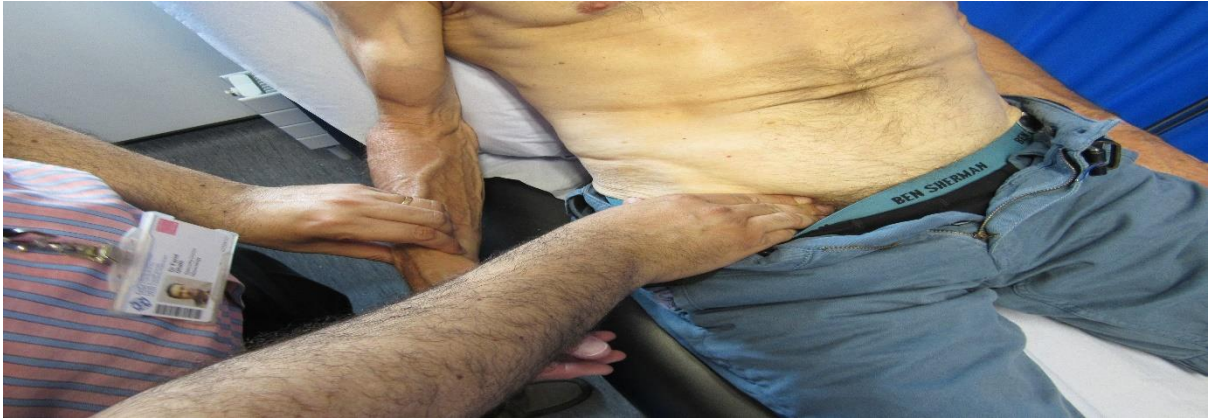

**8. Dorsalis Pedis Artery**

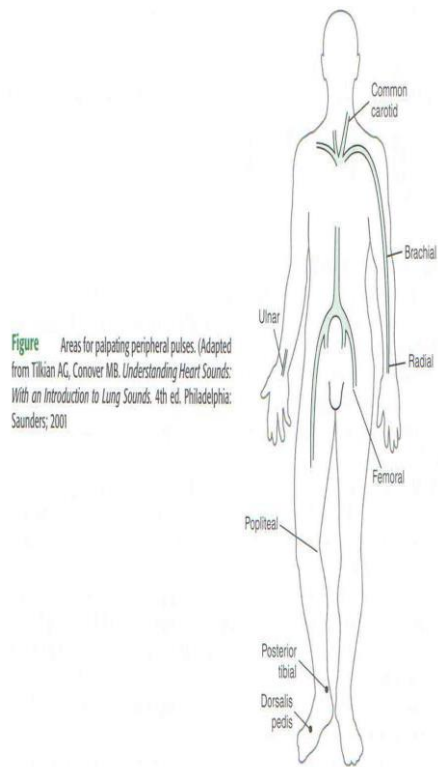


## 9. Posterior Tibial Artery

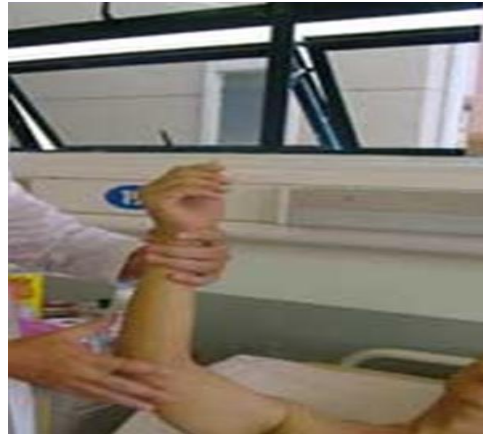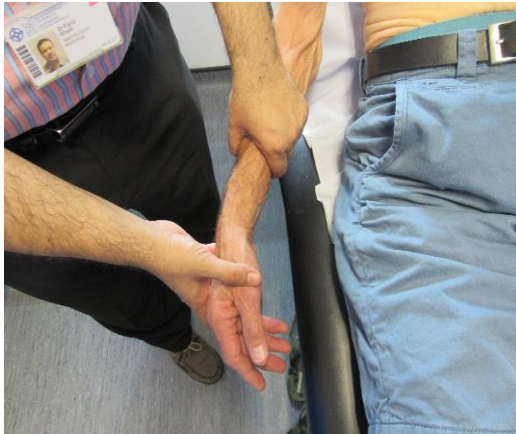## 10. Abdominal Aorta



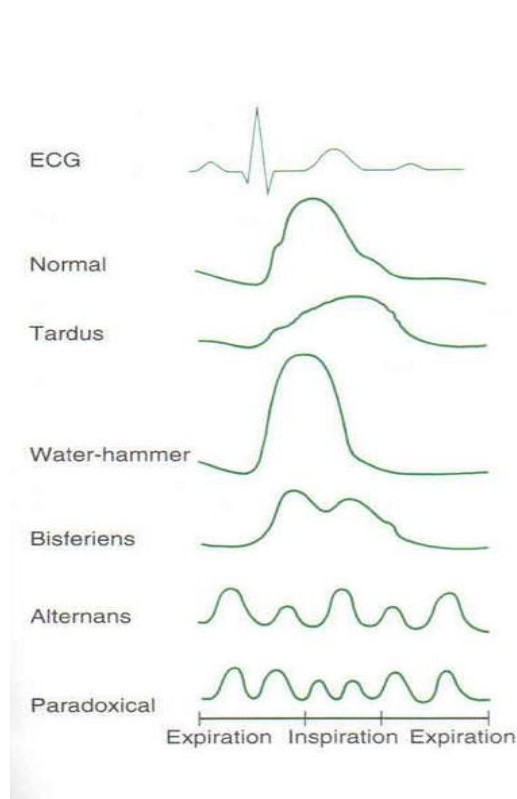
## 11. Femoral Artery palpations and check of radiofemoral delay



### Special Pulse Characters:



### Detection of Water Hammer Pulse



**Figure 1-6** Pulse abnormalities. The electrocardiogram (ECG) demonstrates a P wave, a QRS interval, and a T wave so that the tracings for normal and pathologic pulses can be associated with the timing of the cardiac cycle. (Adapted from Swartz M. *Textbook of Physical Diagnosis: History and Examination*. 6th ed. Philadelphia: Elsevier; 2010 [p. 418, Figure 14-24].)

### Synchronization :

#### 1- Radio-Radial Delay :

- Occur Usually Due To Occlusion Or Stenosis On One Side , Dissection Of Thoracic Aorta Or Aortic Aneurysm .

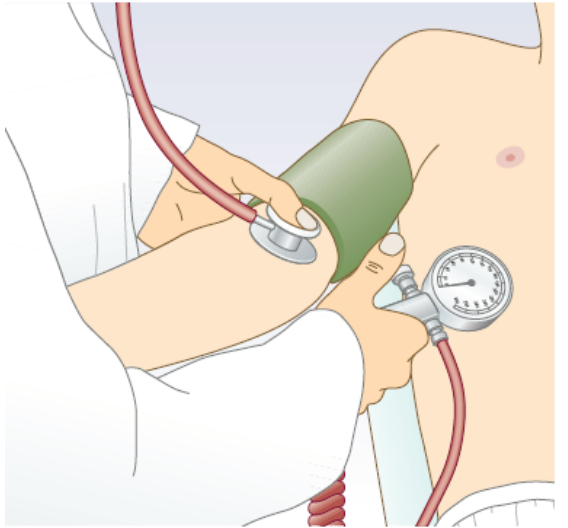
#### 2- Radio-Femoral Delay :

- Suggest The Diagnosis Of Coarctation Of Aorta .

#### 3- Radio-Brachial Delay :

- Occur In Case Of Aortic Stenosis .

## Blood Pressure ( BP ) :

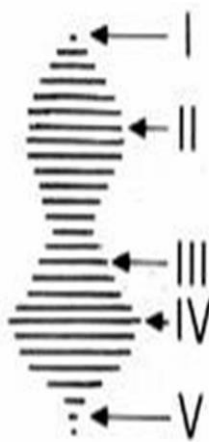


**i** 6.19 British Hypertension Society classification of blood pressure (BP) levels

BP	Systolic BP (mmHg)	Diastolic BP (mmHg)
Optimal	<120	<80
Normal	<130	<85
High normal	130–139	85–89
<b>Hypertension</b>		
Grade 1 (mild)	140–159	90–99
Grade 2 (moderate)	160–179	100–109
Grade 3 (severe)	>180	>110
<b>Isolated systolic hypertension</b>		
Grade 1	140–159	<90
Grade 2	>160	<90

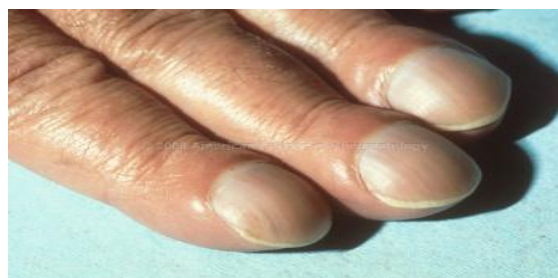## Korotkoff sounds

	Hear:
Systolic →	
Phase 1	A sharp "thud"
Phase 2	A blowing or swishing sound
Phase 3	A softer thud than phase 1
1st Diastolic →	
Phase 4	A softer blowing sound that disappears
2nd Diastolic →	
Phase 5	Silence



## Examination of the Upper Limb

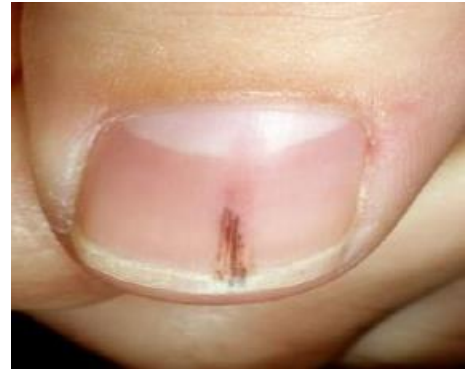☐ Clubbing .



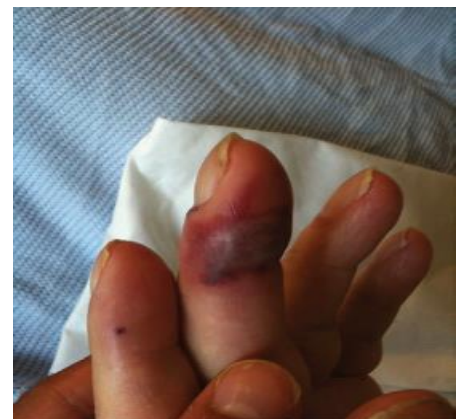☒ **Capillary Refill** : > 2 Seconds ( Peripheral Vascular Disease , Hypothermia , Dehydration , Shock ) .

☒ **Capillary Pulsation ( Quinke's Sign )** : Aortic Regurge .

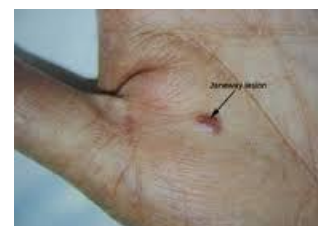☒ **Splinter Hemorrhage** ,



**Osler Node Which Seen In Palmar Surface Of Fingertip** : Infective Endocarditis

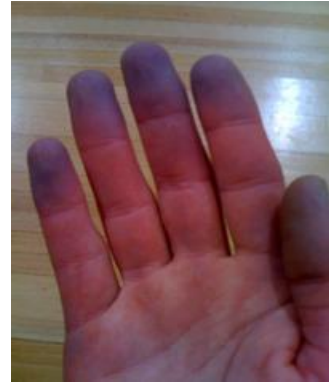

**Janeway Lesions** : Infective Endocarditis



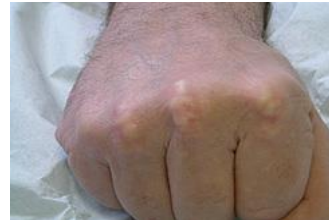**, Petechial Rash , Evidence Of IV Drug Abuse** : Infective Endocarditis .

☒ **Peripheral Cyanosis** .



☐ **Pallor Which Seen In Palmar Creases .**

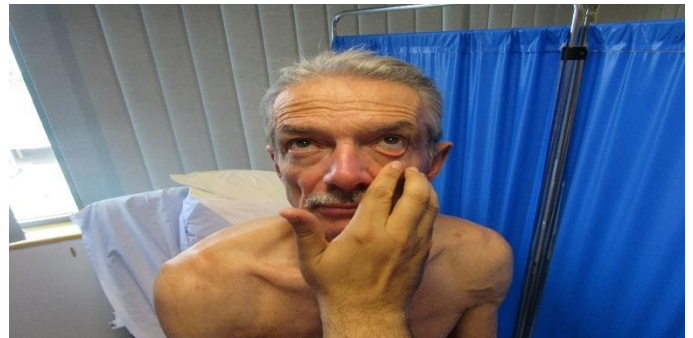☐ **Tendon Xanthoma ( Yellowish Discoloration Of Tendon At Wrist ) :  
Hyperlipidemia .**



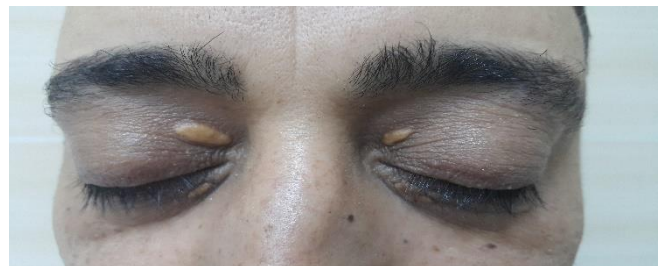### Examination of Head & Neck :

☐ **Eye :**

- **Jaundice .**
- **Pallor : Anemia**
- **Conjunctival Hemorrhage : Infective Endocarditis .**

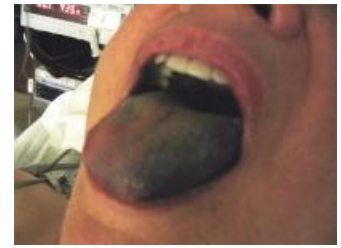

- **Xanthelasma : Hyperlipidemia .**



**☒ Mouth :**

- **Cyanosis** : Lips For Peripheral Cyanosis & Tongue For Central Cyanosis .



**☒ Cheeks :**

- **Mitral Facies** : Severe Mitral Stenosis .



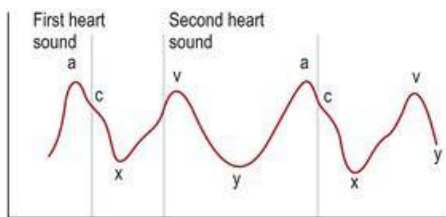
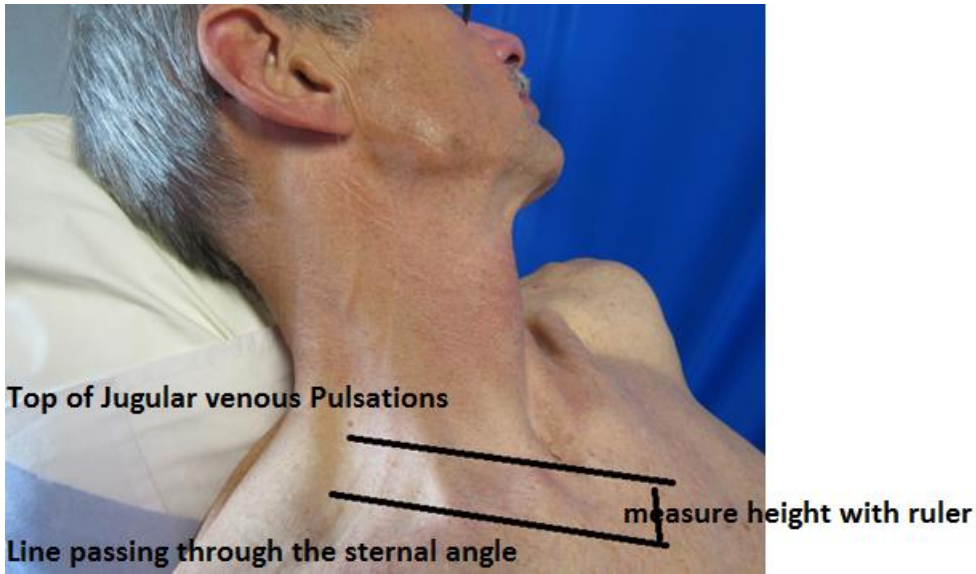
**☒ Neck :**

- Lymph Nodes (See respiratory system examination).
- Jugular Vein .
- Carotid Artery .

**5. Neck veins and carotid arterial pulsations**

**JVP**

A. [www.ottawaheart.ca](http://www.ottawaheart.ca)  
B. [soperedi.wordpress.com](http://soperedi.wordpress.com)  
C. [www.zen104556.zen.co.uk](http://www.zen104556.zen.co.uk)



Normal waveforms of the jugular venous pulse.



venous waves.mp4

### JVP Waves :

- ❑ **a - Wave** : Caused By Atrial Contraction .
- ❑ **c - wave** : Due To Closure of Tricuspid Valve .
- ❑ **x - Descent** : Atrial Relaxation .
- ❑ **v - Wave** : Increasing pressure in right atrium with atrial filling .
- ❑ **y - Descent** : Commencement of Ventricular Filling As Tricuspid Valve Opens .

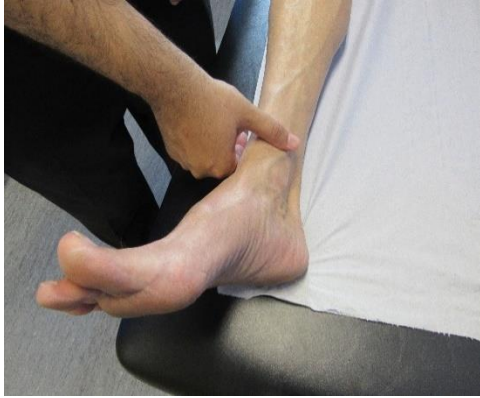### How to differentiate between arterial and venous neck pulsations?



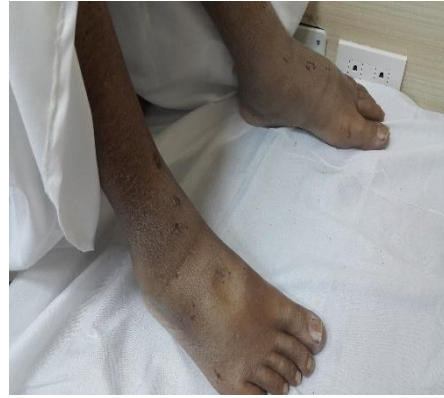Types of neck pulsations.mp4

## Examination of the Lower Limb

- Skin Changes , Muscle Wasting , Loss Of Hair .
- **Oedema** : Pitting / Non-Pitting - Unilateral / Bilateral - Level .
- **Pulse** : Femoral - Popliteal - Dorsalis Pedis - Posterior Tibial ( See pulse section above) .



Check Lower limb oedema

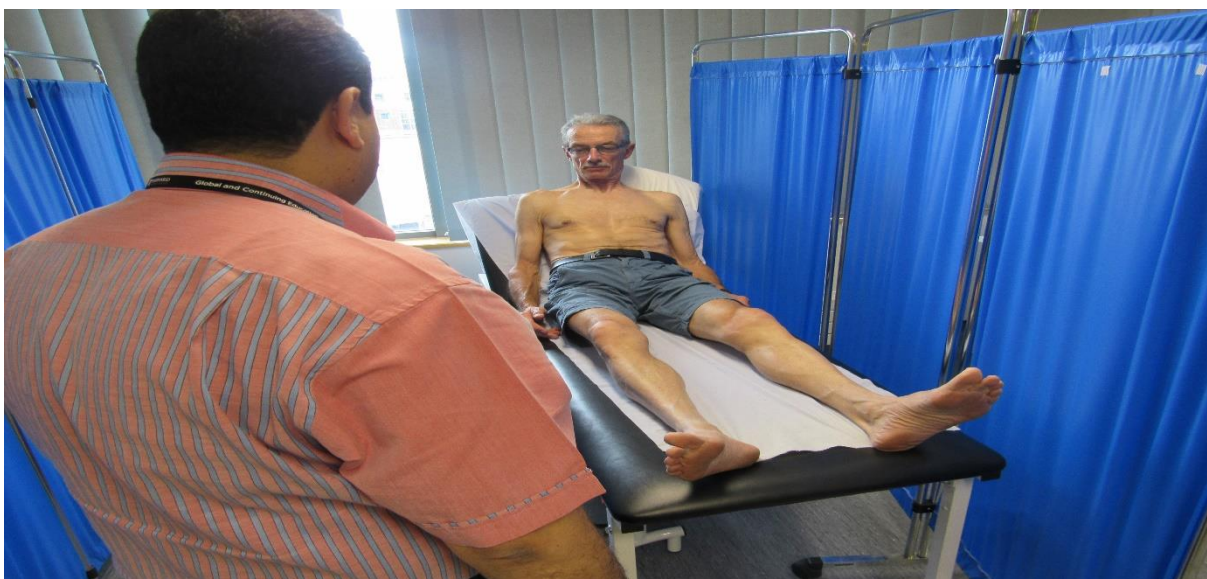

Pitting oedema

## Local Heart Examination :

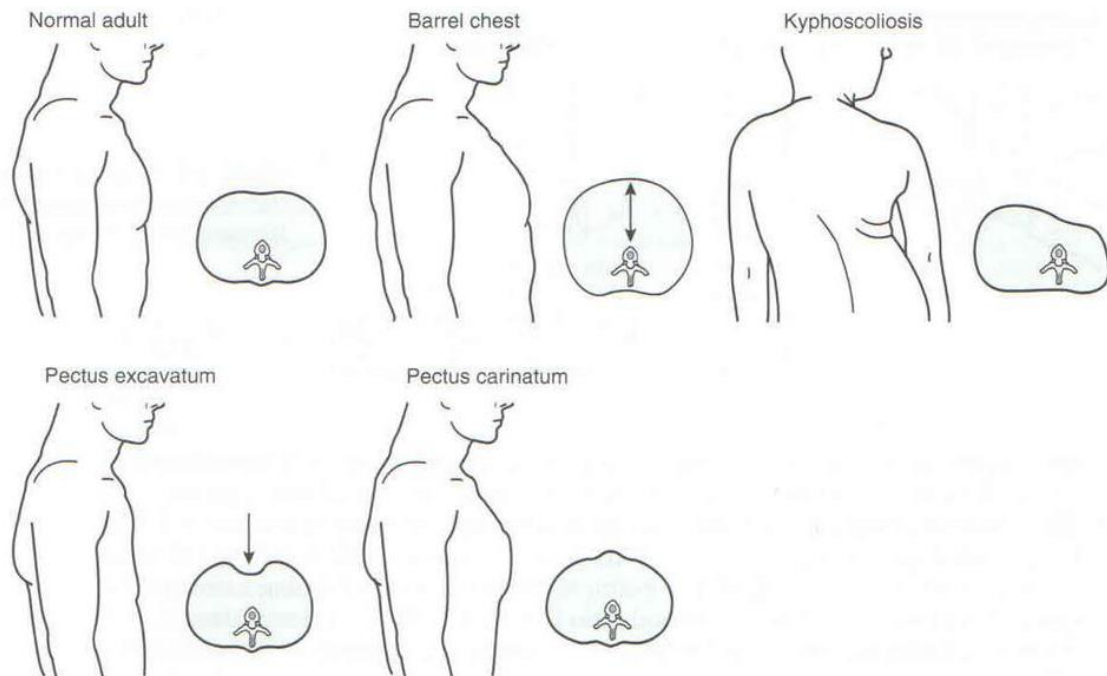
### Inspection :

Observe the patient from the end of the bed



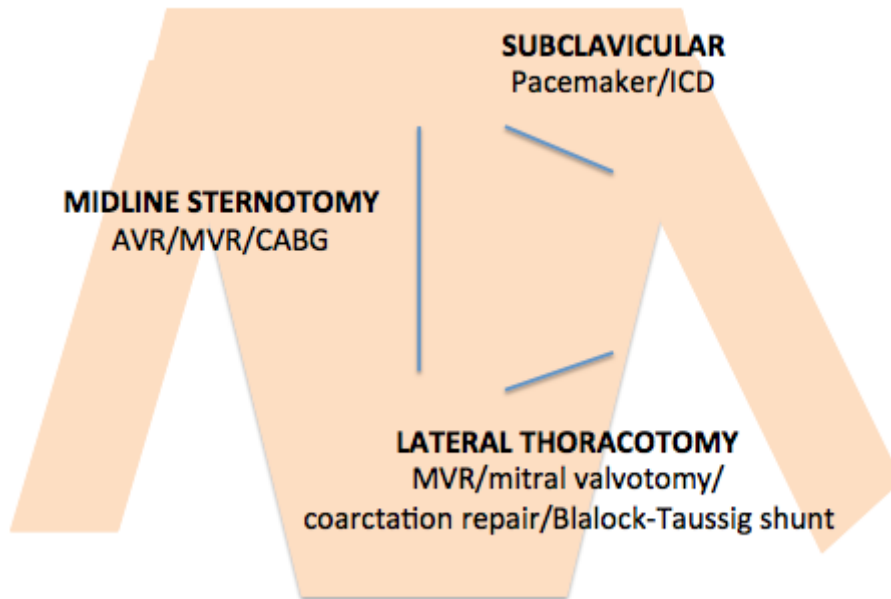
1. **Symmetry** : localised bulge or retraction

2. **Deformity** : Kyphosis , Scoliosis , Pectus Excavatum , Pectus Carinatum

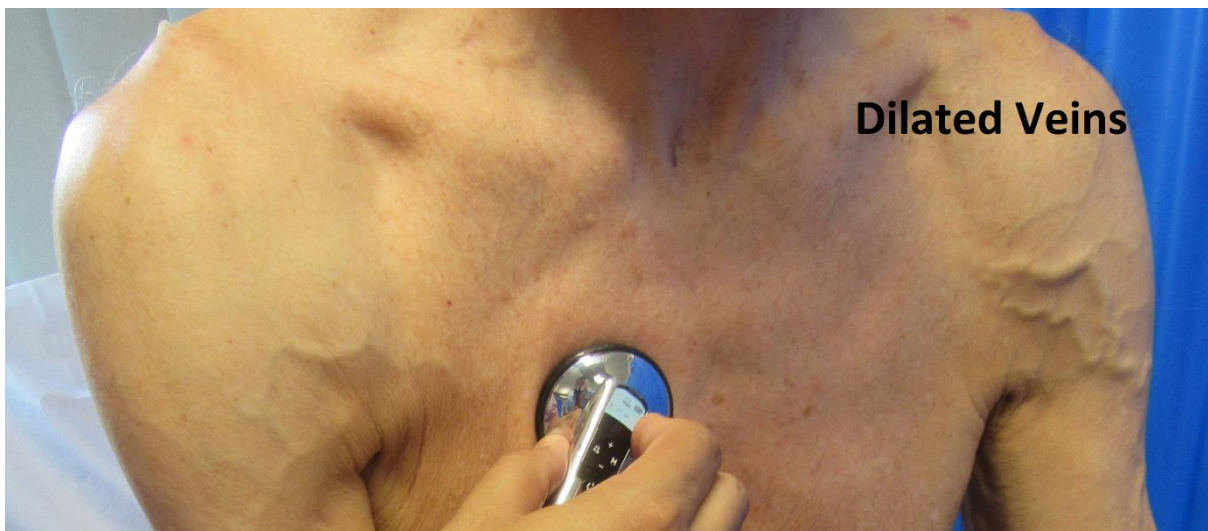

**Figure** Thoracic deformities. (Adapted from Lehrer S. *Understanding Lung Sounds*. 3rd ed. Philadelphia: Saunders; 2002)

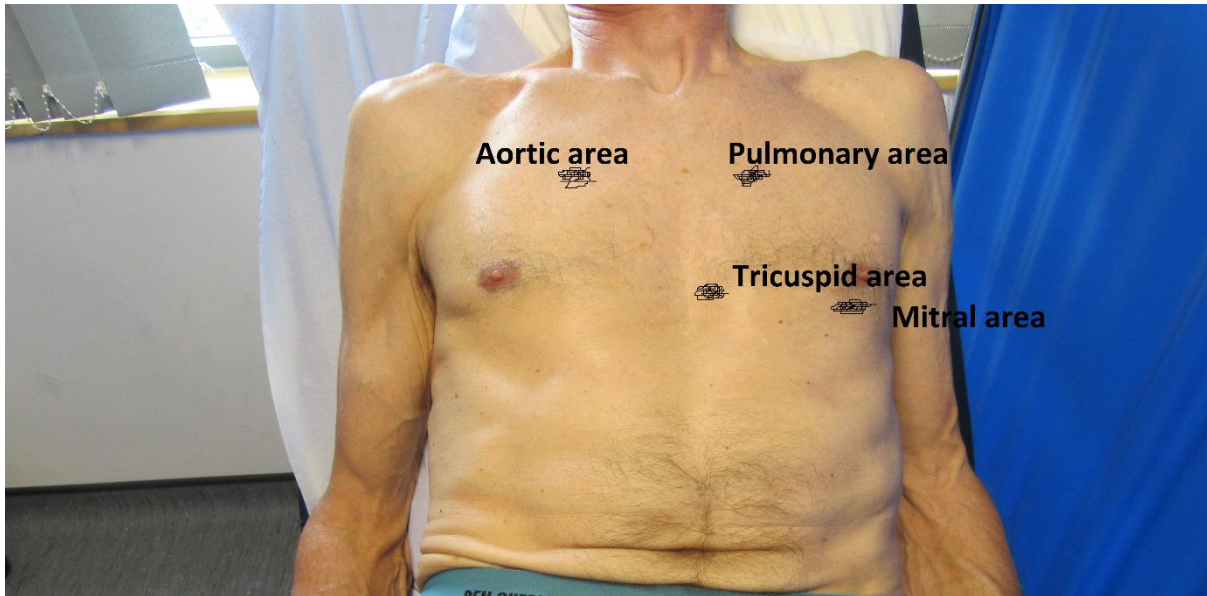
3. **Previous Scars** : Median Sternotomy , Lateral Thoracotomy .



#### 4- Dilated Veins



#### 5. Any Visible Pulsations : Determine The Site .



- **Epigastric Pulsation** : Right Ventricle , Aorta Or Left lobe of the liver ( Differentiated By Palpation ) .
- **Lt Parasternal Pulsation** : Right Ventricle Enlargement.
- **Aortic Area Pulsation ( 2<sup>nd</sup> Right ICS )** : Aortic Aneurysm , Systemic Hypertension .
- **Pulmonary Area Pulsation ( 2<sup>nd</sup> Left ICS )** : Pulmonary Hypertension .
- **Suprasternal / Carotid Pulsation** : Aortic Regurgitation ( Corrigan's Sign ) .

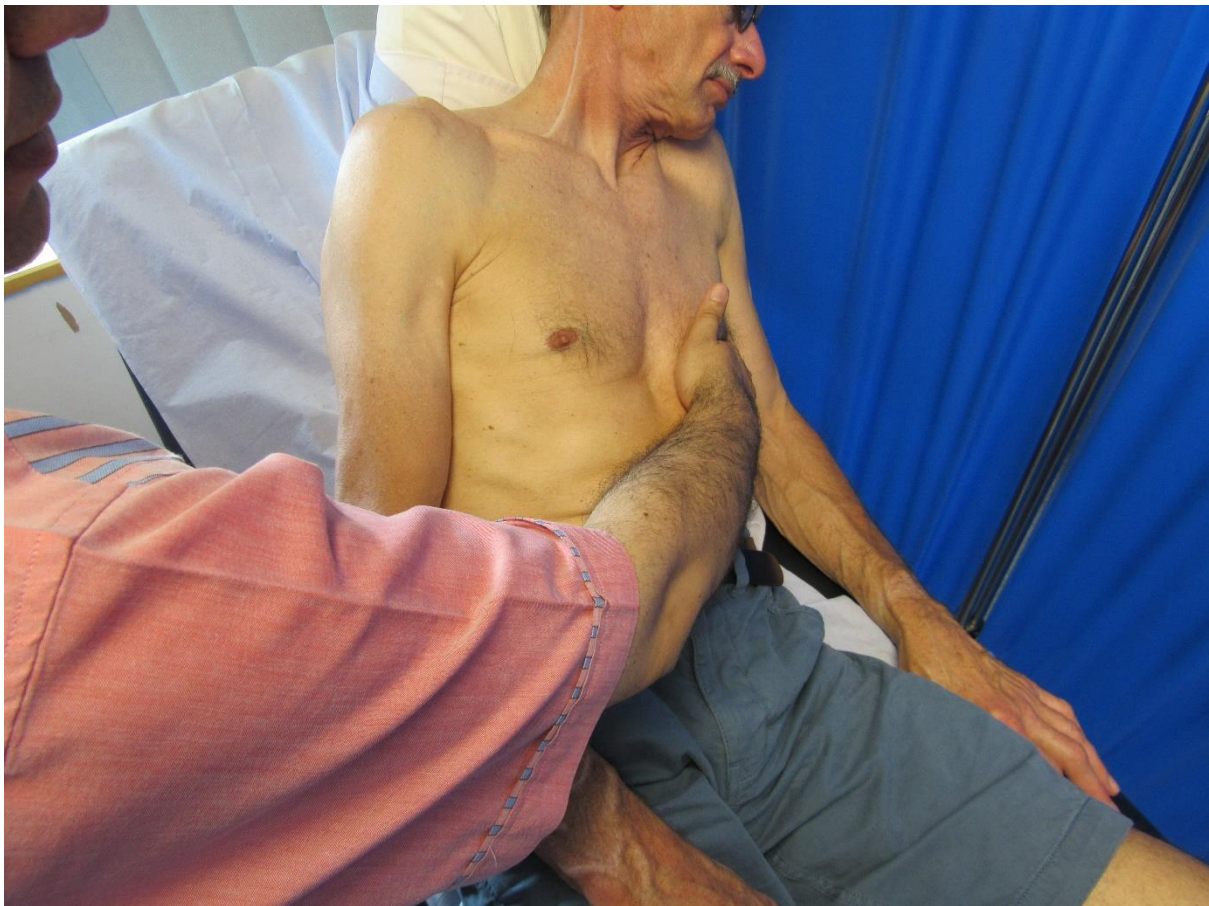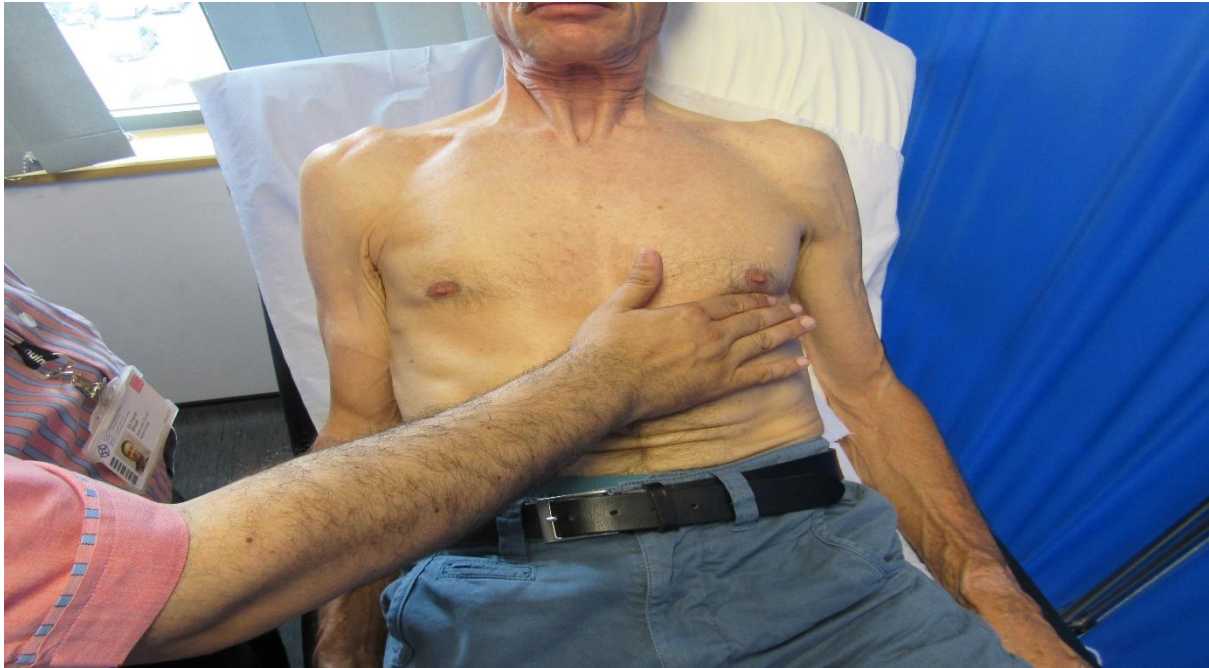## Palpation:

" Don't Forget To Warm Your Hand "

### 1- Apex Beat .

- **Definition** : Lower Most And Outer Most Visible And Palpable Pulsation Over The Chest .
- **Normal Site** : 5<sup>th</sup> Left ICS ,1 Cm Medial To Mid-Clavicular Line .
- **Normal Size** : Less Than 2 Intercostal Space And Localized .
- **Normal Character** : Gentle Tap .

**Apex beat** – normal position is 5th intercostal space – mid-clavicular line

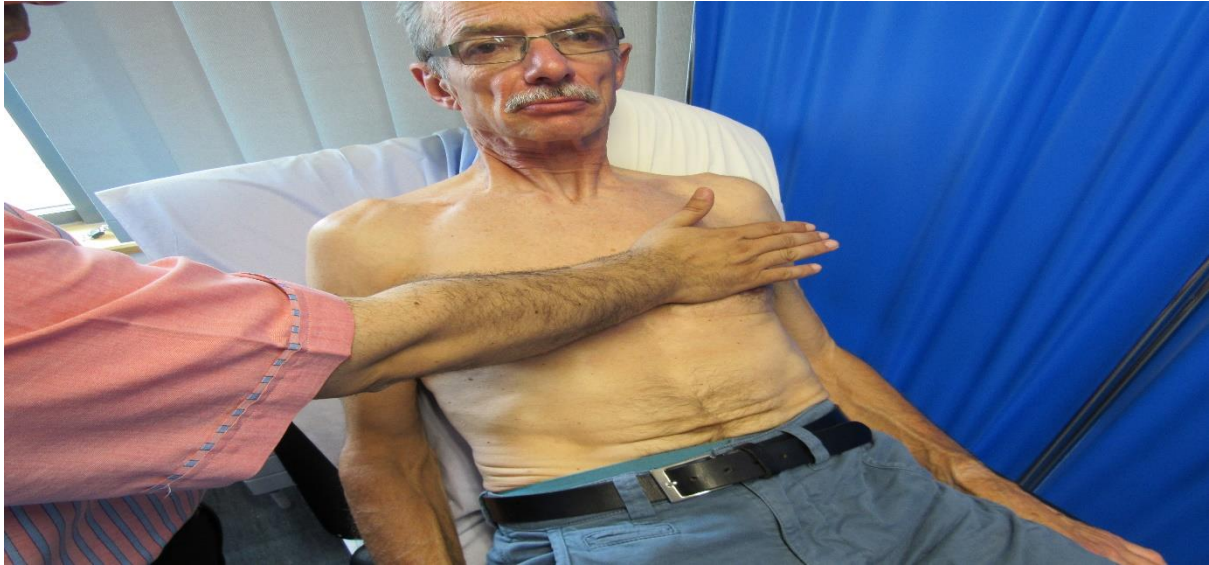

left lateral decubitus

## 2. Parasternal Heave :

- Rest The Heel Of The Hand Just To The Left Of The Sternum With The Fingers Lifted Slightly Off The Chest .

- Normally No Impulses But In Right Ventricular Enlargement , The Heel Of Hand Is Lifted Off The Chest With Each Systole .



### 3. Other Pulsations

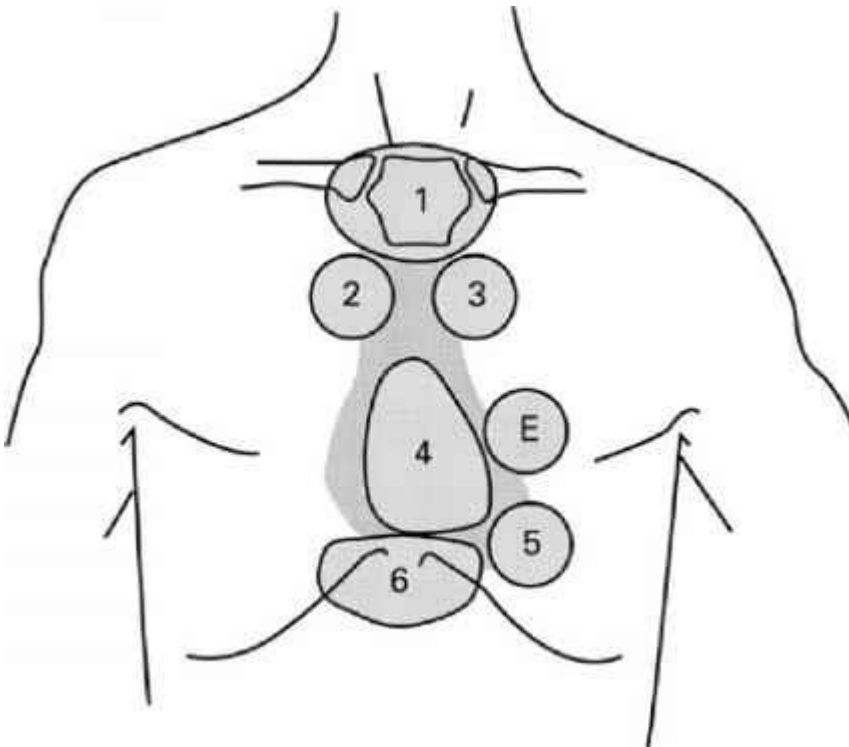
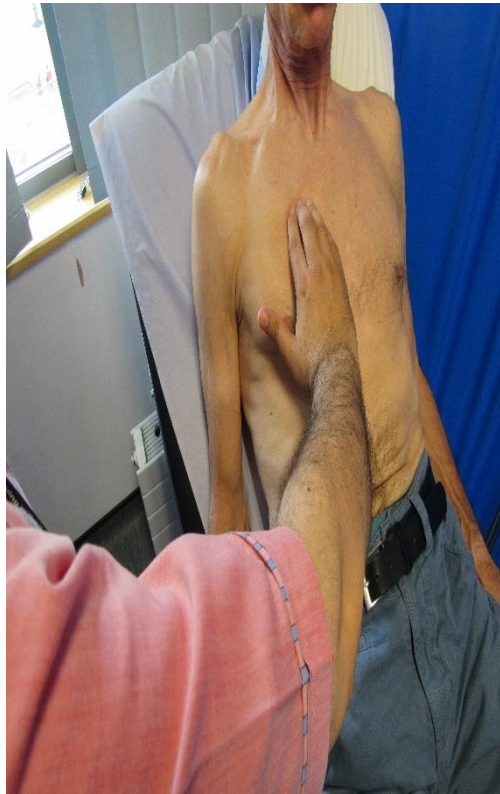
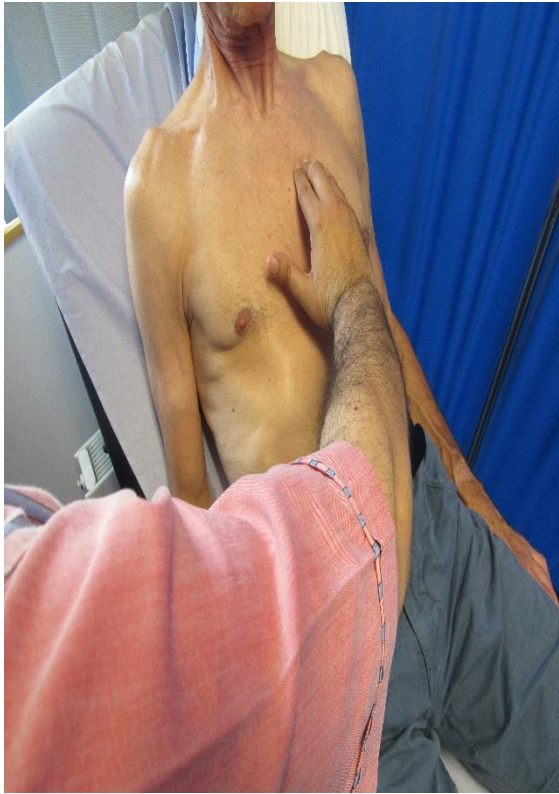

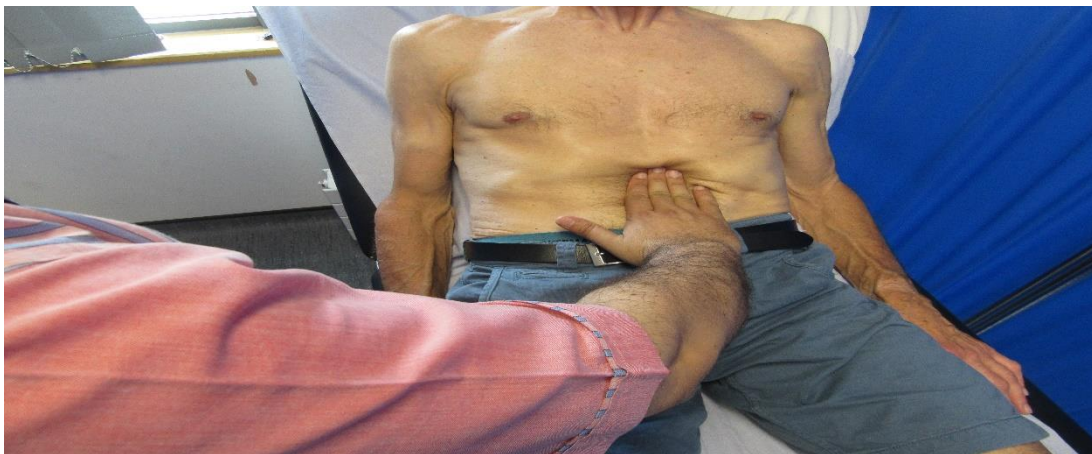Figure : Seven areas to be examined for abnormal cardiovascular pulsations by inspection and palpation. (From Schlant RC, Hurst JW.)

**Pulmonary area pulsations**

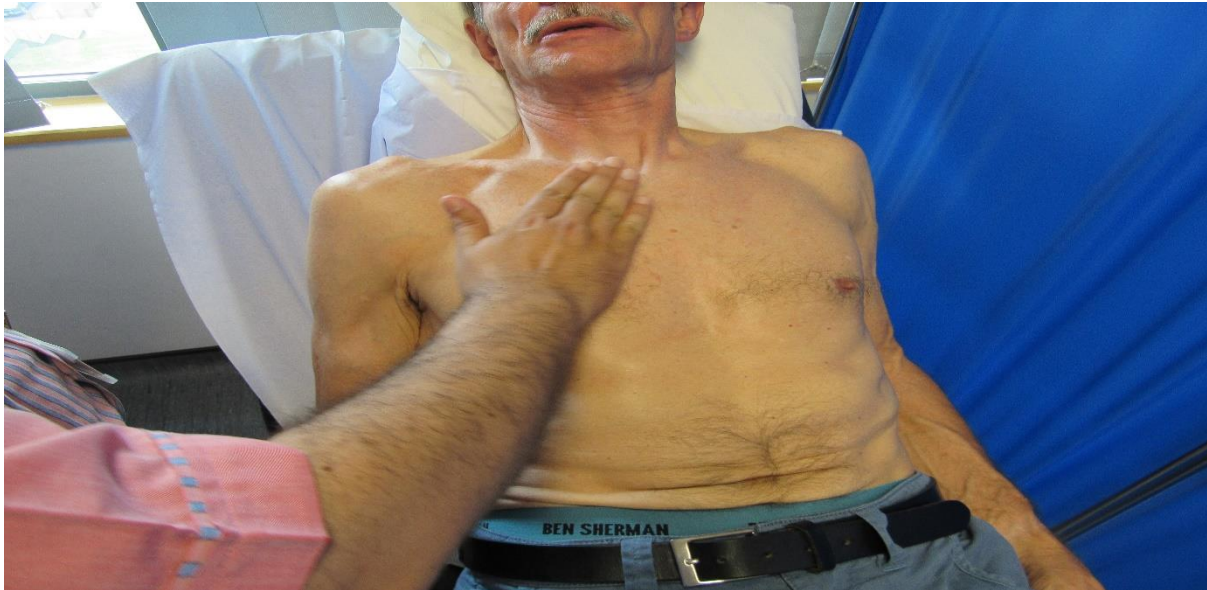**Aortic area pulsations**



### Epigastric Pulsations



### 4. Thrills ( Palpable Murmurs ) :



Location of Thrills and Associated Disorders

Location of Thrill	Associated Disorder
Over the base of the heart at the 2nd intercostal space, just to the right of the sternum, during systole	Aortic stenosis
At the apex during systole	Mitral regurgitation
To the left of the sternum at the 2nd intercostal space	Pulmonic stenosis
To the left of the sternum at the 4th intercostal space	Small muscular ventricular septal defect (Roger disease)

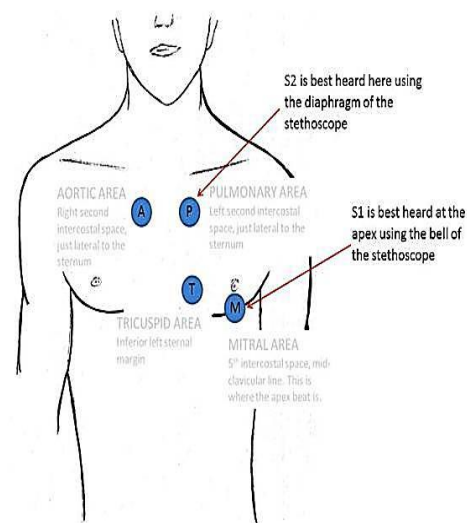
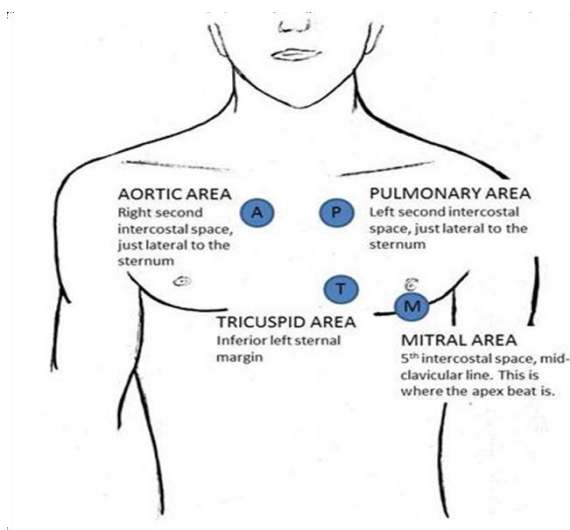
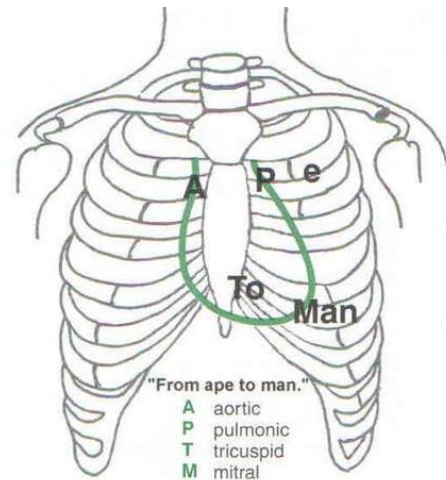
## Auscultation:

### # Component Of Auscultation :

- 1- Heart Sound .
- 2- Murmurs .
- 3- Additional Sounds .

### 1. Heart Sounds :

**Figure 1-13** Auscultatory anatomy: "from **ape** to **man**" is a mnemonic to help you remember where best to auscultate to detect **aortic**, **pulmonic**, **tricuspid**, and **mitral** murmurs.



### A- 1<sup>st</sup> Heart Sound ( S<sub>1</sub> ) :

- Due To Closure Of Mitral And Tricuspid Valves ( Indicate Beginning Of Ventricular Systole ) .

- Heard At :

☑ Mitral Area : 5<sup>th</sup> Left ICS , Mid-Axillary Line ( By Bell Of Stethoscope ) .

☑ Tricuspid Area : 4<sup>th</sup> ICS , Parasternal ( By Diaphragm Of Stethoscope ) .

### B- 2<sup>nd</sup> Heart Sound ( S<sub>2</sub> ) :

- Due To Closure Of Pulmonary And Aortic Valves .

- Heard At :

☑ Pulmonary Area : 2<sup>nd</sup> Left ICS .

☑ Aortic Area: 2<sup>nd</sup> Right ICS .

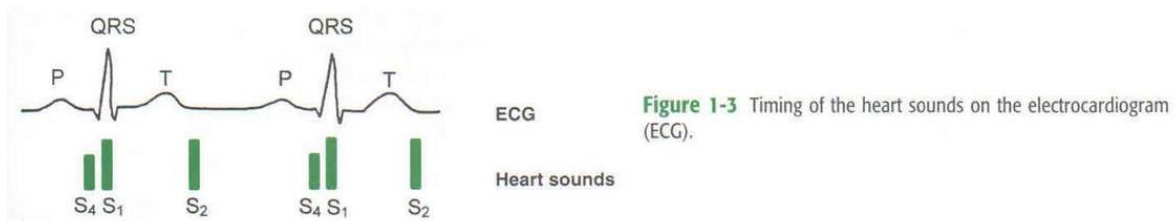


Figure 1-3 Timing of the heart sounds on the electrocardiogram (ECG).

### C- 3<sup>rd</sup> Heart Sound ( S<sub>3</sub> ) :

- This Is A Low-Pitch Mid-Diastolic Sound Occurring After S<sub>2</sub> . ( Can Just Be Heard With The Bell ) .
- **Physiological** : Soft Sound Heard Only At The Apex, Normal In Fit Adults Up To Age 30 .
- **Pathological** : As In left Ventricular Failure .

### D- 4<sup>th</sup> Heart Sound ( S<sub>4</sub> ) :

- This Is A Late Diastolic Sound ( Just Before S<sub>1</sub> ) .
- Caused By Atrial Contraction Against A Stiff Ventricle .
- Never Physiological .
- Causes Are Hypertrophic Cardiomyopathy , Aortic Stenosis, Pulmonary HTN , Pulmonary Stenosis .
- Don't Occur If The Patient Is In Atrial Fibrillation .

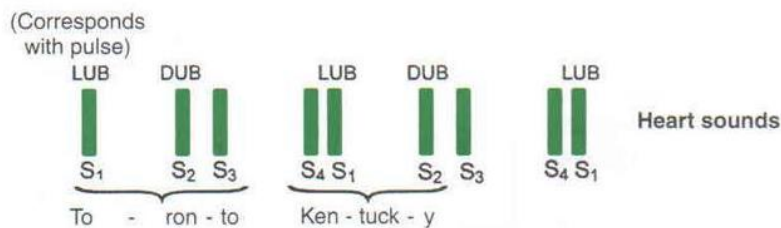


Figure 1-14 Timing of extra heart sounds in the cardiac cycle.

### Listen to normal heart sounds:

<http://www.easyauscultation.com/course-contents?courseid=22>

### 2- Murmurs :

- Comment On ( Timing , Site Of Maximum Intensity , Radiation , Grade , Relation To Position ) .

#### Timing :

- You Must Decide Whether The Noise Occurs In Systole Or Diastole ( Compare To Carotid Artery To Be Sure ) .

#### # Systolic Murmurs :

##### - Ejection Systolic :

- ☑ Start Quietly At The Beginning Of Systole .
- ☑ Caused By : Pulmonary Stenosis , Aortic Stenosis .

##### - Pansystolic :

☑Lasts For The Whole Of Systole And Tends To Be Due To Backflow Of Blood From A Ventricle To An Atrium .

☑Caused By : Tricuspid Regurgitation , Mitral Regurgitation ,VSD .

- **Late Systolic :**

☑There Is An Audible Gap Between  $S_1$  And The Start Of The Murmur , Which Then Continues Until  $S_2$  .

☑Typically This Is Due To Tricuspid Or Mitral Regurgitation Through A Prolapsing Valve .

# **Diastolic Murmurs :**

- **Early Diastolic :**

☑It Starts Loudly At  $S_2$  And Decrescendos During Diastole .

☑Usually Due To Aortic Or Pulmonary Regurgitation .

- **Mid-Diastolic :**

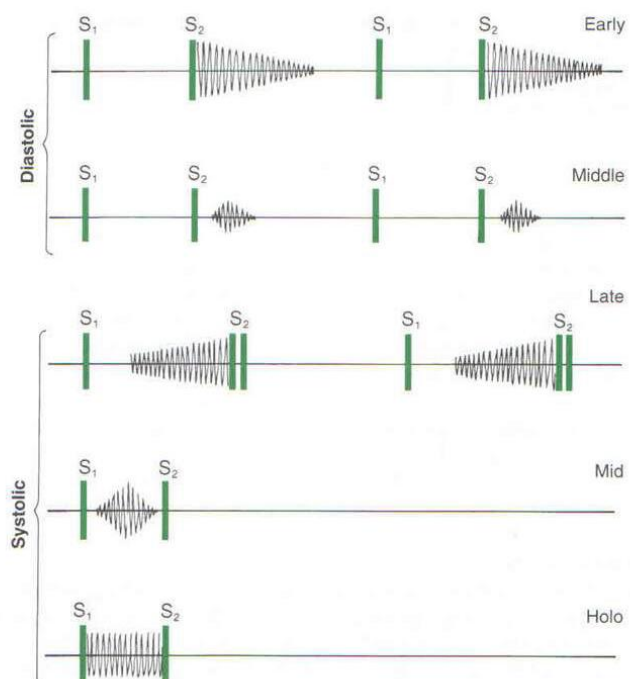
☑Begin Later In Diastole And May Be Brief Or Continue Up To  $S_1$  .

☑Usually Due To Mitral Or Tricuspid Stenosis .

# **Continuous Murmurs :**

- Heard Throughout Both Systole And Diastole .

- Common Causes : PDA , A-V Fistula .



**Figure 1-11** Description of the timing of murmurs in the cardiac cycle. (Adapted from Tilkian AG, Conover MB. *Understanding Heart Sounds: With an Introduction to Lung Sounds*. 4th ed. Philadelphia: Saunders; 2001 [p. 135, Figure 12-3].)

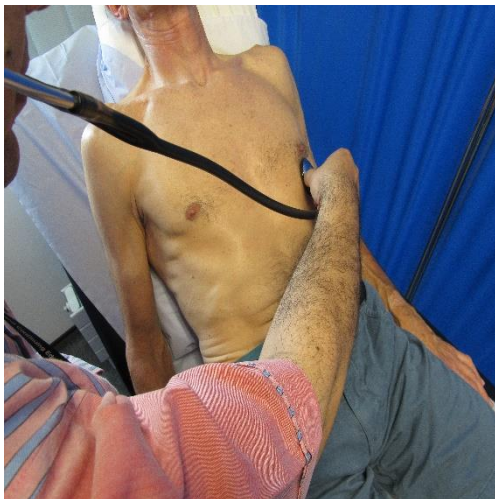


**Figure 1-12** Description of the electrocardiographic "shape" of a murmur. (Adapted from Tilkian AG, Conover MB. *Understanding Heart Sounds: With an Introduction to Lung Sounds*. 4th ed. Philadelphia: Saunders; 2001 [p. 135, Figure 12-4].)

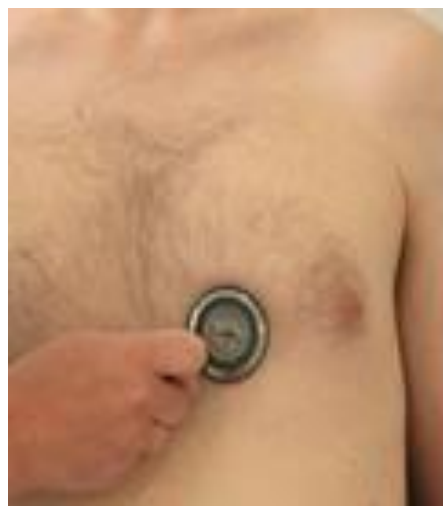**Site Of Maximum Intensity :**

- The Site That You Can Hear The Murmur Louder .
- Aortic Regurgitation Is Heard Louder If You Ask The Patient To Sit Up And Lean Forward , Then Listen At The Left Sternal Border .
- Mitral Stenosis Is Louder If You Ask The Patient To Lie On Their Left Side , Then Listen With The Bell At The Apex .

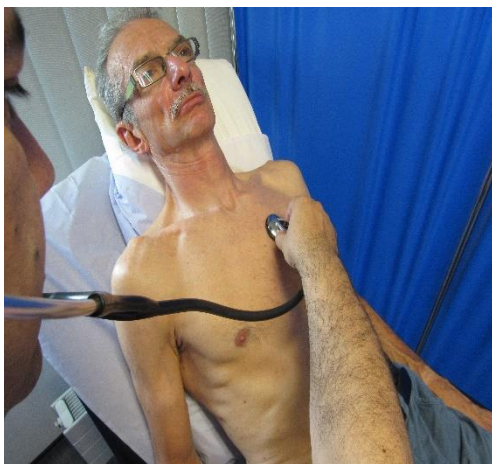**Mitral Area**



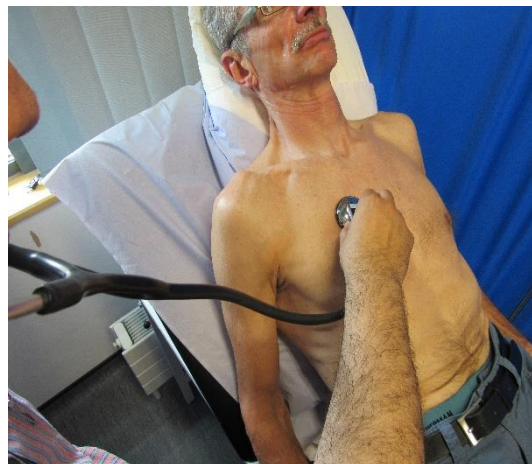**Tricuspid Area**



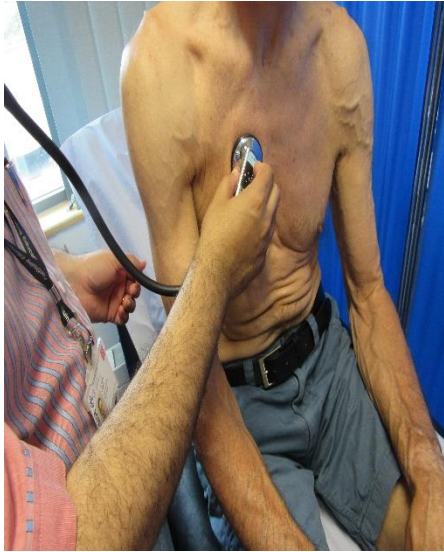**Pulmonary Area**



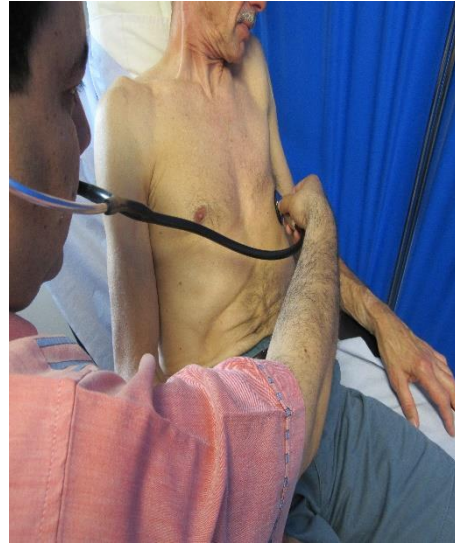**Aortic Area**



**Best Position for Aortic valve Auscultation**

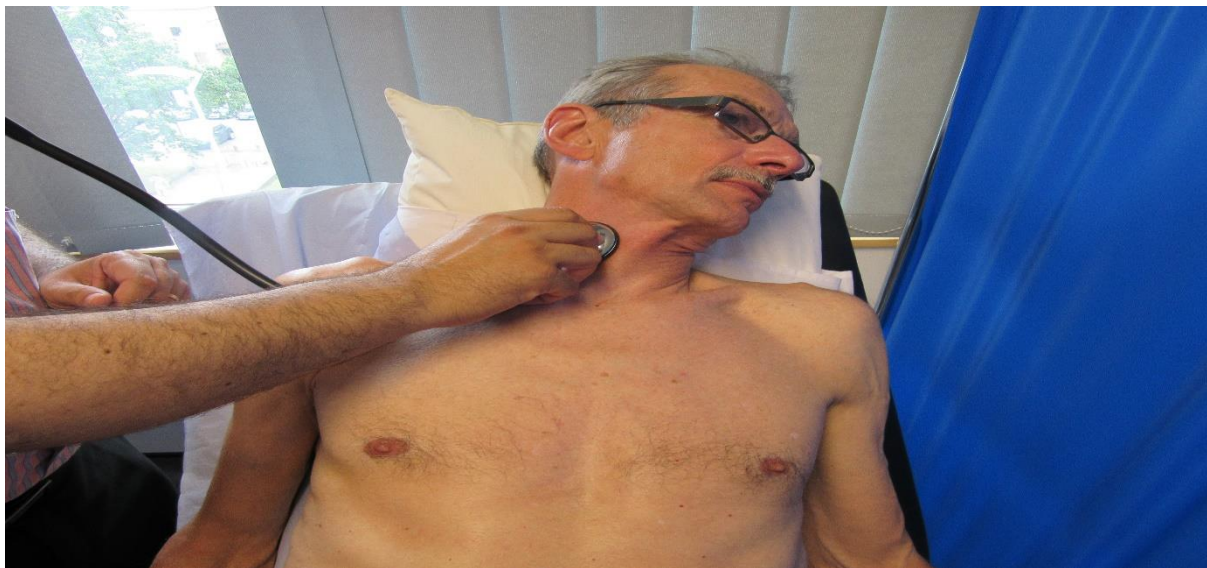


**Left Lateral Pos. for Mitral stenosis**



**Radiation :**

- Murmur Of Aortic Stenosis Will Radiate To The Carotids .
- Murmur Of Mitral Regurgitation radiates to The Left Axilla .



**Grade :**

- Grading The Murmurs According To Loudness Into Six Grades ( Levine's Grading System ) :

## Heart Murmur Intensity

Grade	Description
1	Barely audible
2	Soft but easily heard
3	Loud without a thrill
4	Loud with a thrill
5	Loud with minimal contact between stethoscope and chest
6	Loud with no contact between stethoscope and chest

### Listen to Heart murmurs:

<http://www.easyauscultation.com/heart-murmur>

### 3- Additional Sounds :

#### A- Opening Snap :

- Sudden Opening Of The Stiffened Valve Can Cause An Audible High-Pitched Snap In Early Diastole .

- Present In Mitral Or Tricuspid Stenosis .

#### B- Systolic Ejection Click :

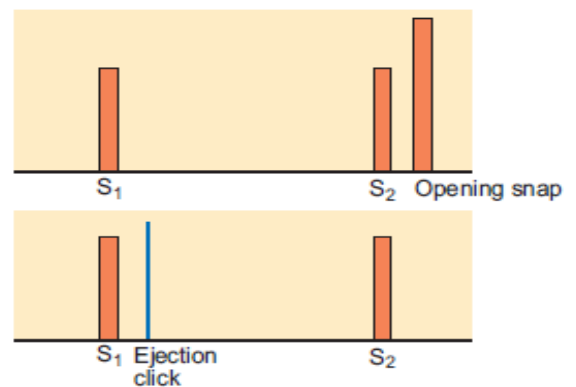
- High-Pitched Click Heard Early In Systole , Caused By The Opening Of A Stiffened Semilunar Valve .

- Present In Aortic Stenosis , And Associated With Bicuspid Aortic Valves .

#### C- Pericardial Friction Rub :

- Scratching Sound Has Three Components Occurring At Any Time During Cardiac Cycle , Heard With Each Heartbeat And Caused By Inflamed Pericardial Membranes .

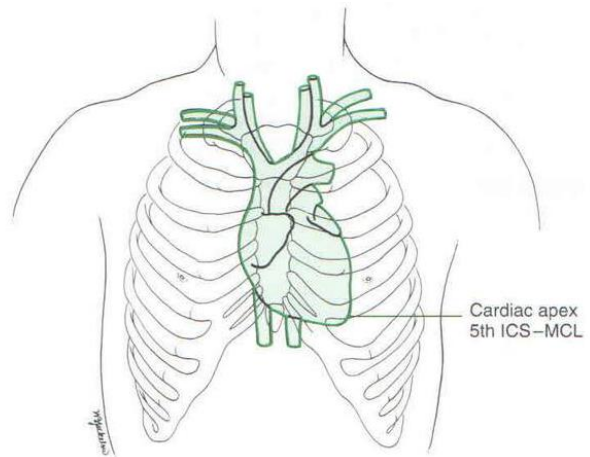
- It Is Louder As The Patient Is Sitting Up , Leaning Forward , And Heard Best In Expiration .



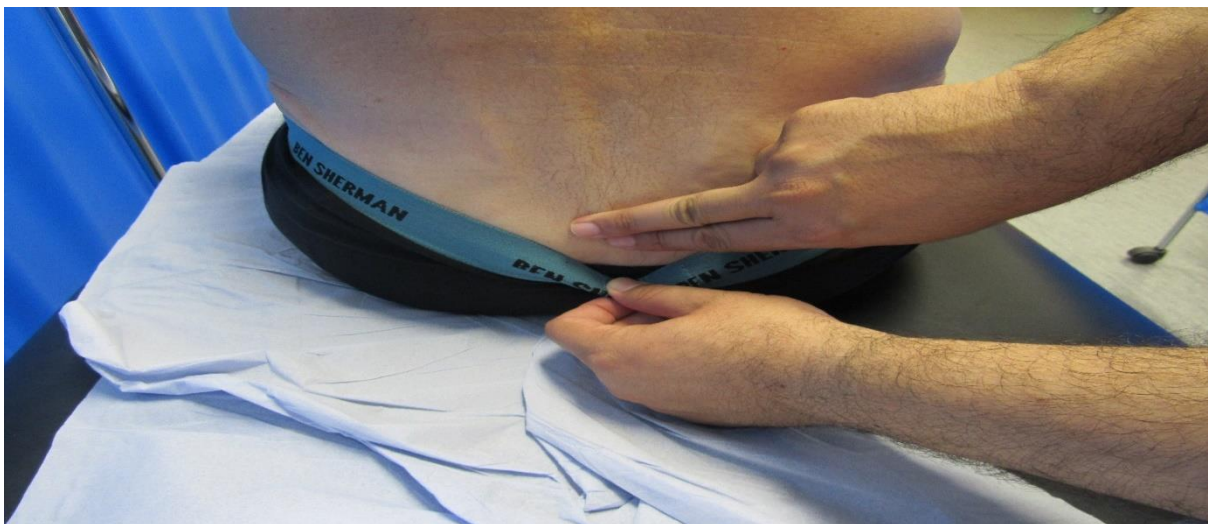## Additional Informations

### 1- Surface Anatomy of the heart:

**Figure** Surface anatomy of the heart. ICS, intercostal space; MCL, midclavicular line. (Adapted from Swartz M. *Textbook of Physical Diagnosis: History and Examination*. 6th ed. Philadelphia: Elsevier; 2010)



## 2- Check Sacral Oedema



## References :

- 1- OSCE And Clinical skills handbook: Hurley KF, second edition. Elsevier Canada 2011
- 2- Online osceskills website. [www.osceskills.com](http://www.osceskills.com)
- 3- Macleod's clinical examination ,thirteenth ed. 2013
- 4- Step by Step Clinical examination Skills:Iqbal F , first edition 2009
- 5- Merck Manual:cardiovascular examination.profesional online version.