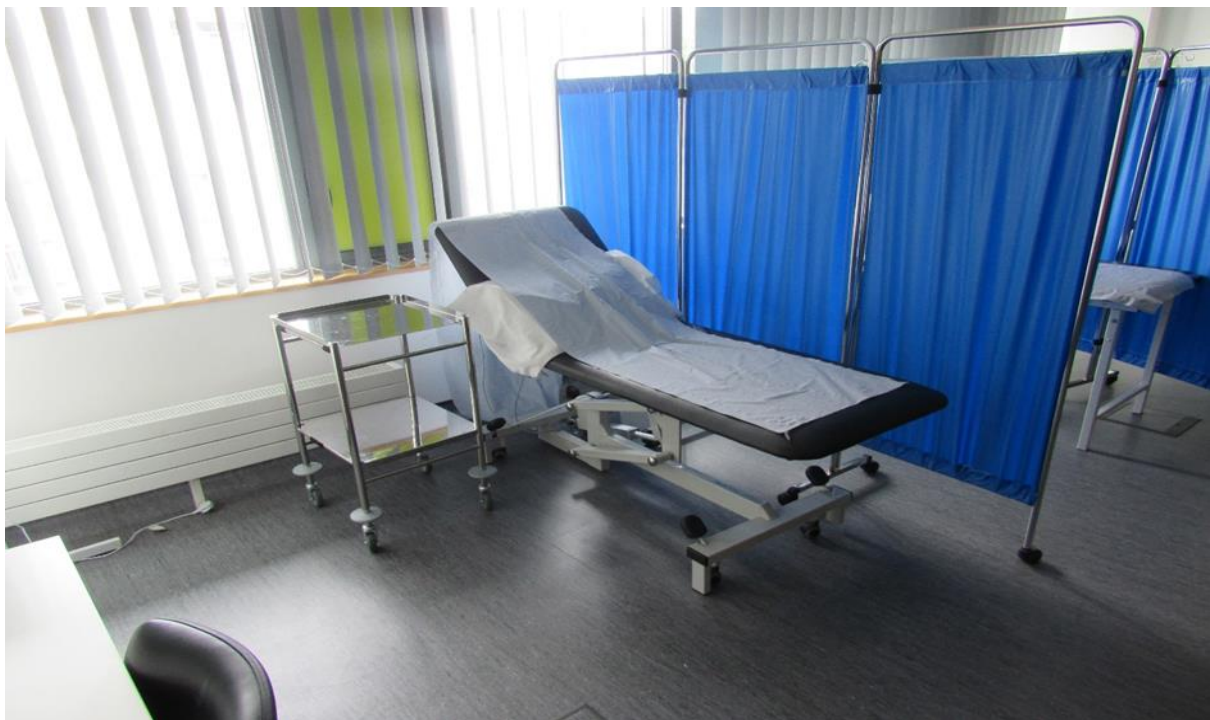

An Illustrated Guide For Abdominal and Genitourinary Examination

Bedside Teaching for 2nd year medical Students



Prepared by:

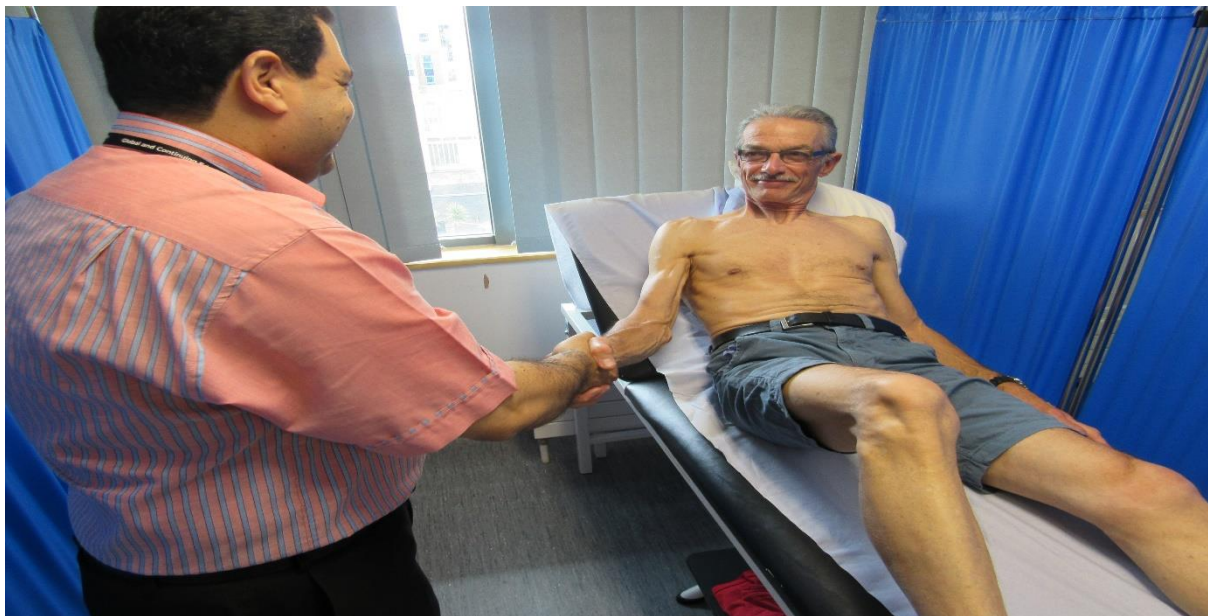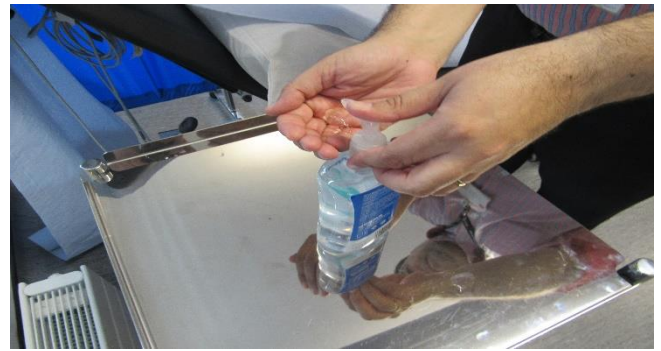
Dr. Farid Ghalli

Clinical Teacher (Hon)

November 2016

Before Examination :

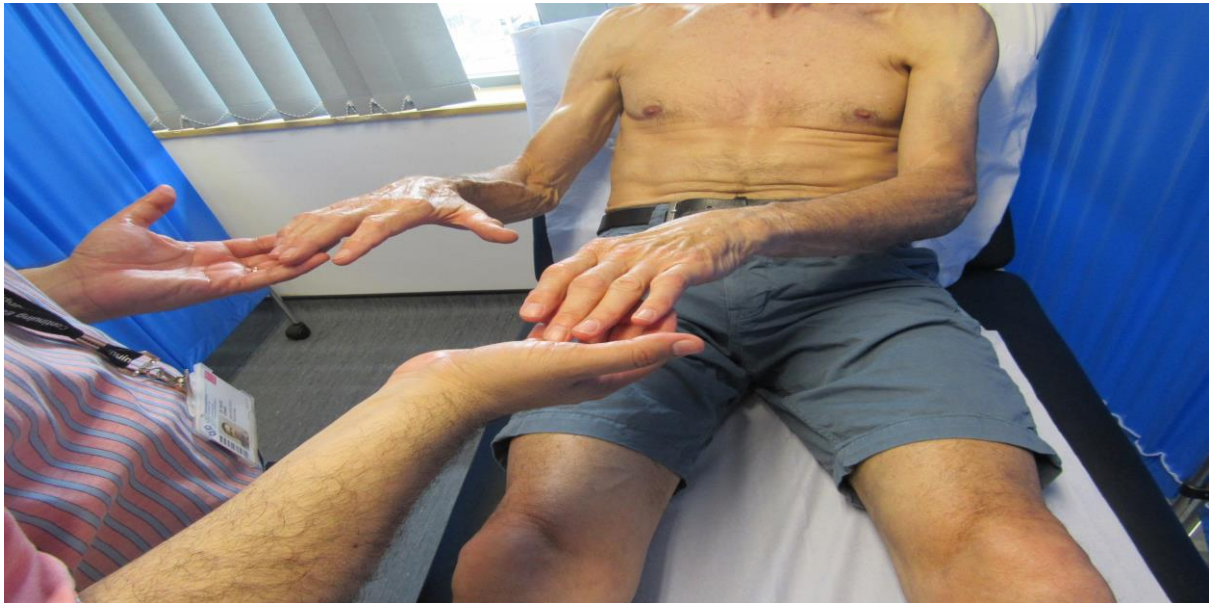Wash hands
Introduce yourself
Confirm patient details – *name / DOB*
Explain the examination
Gain consent
Expose the patient's chest
Position patient at 45°
Ask patient if they have pain anywhere before you begin!



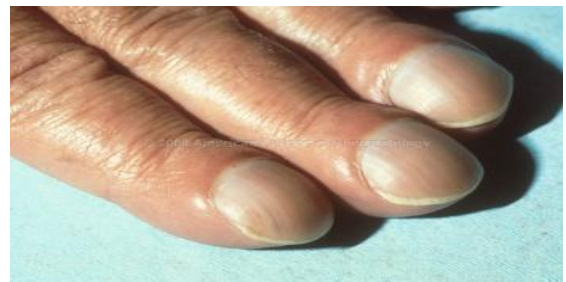General Examination

- ☐ **Appearance** : Looks Well/Ill , Consciousness , Alert .
- ☐ **Body Built** : Average , Thin , Obese (Depends On BMI) .
- ☐ **Color** : Pale , Cyanosed , jaundiced.
- ☐ **Decubitus** : Patient's position in bed .
- ☐ **Distress** : Difficulty In Breathing (Dyspnoeic), Abdominal distension .

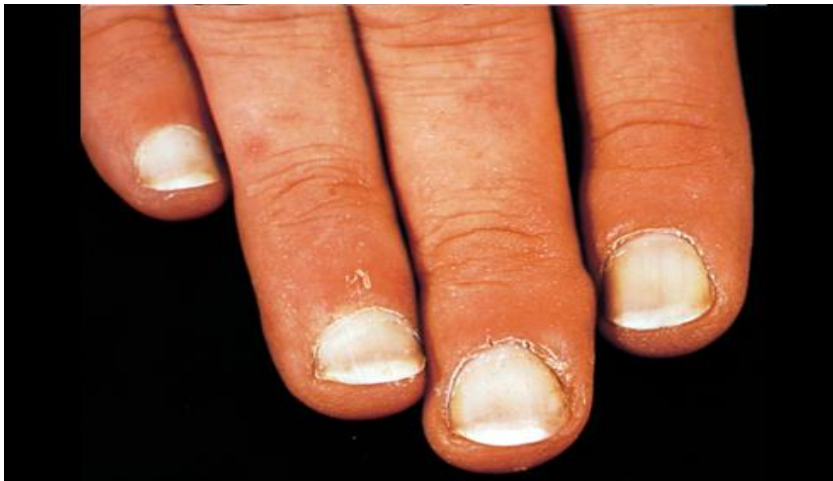Examination of the Upper Limb



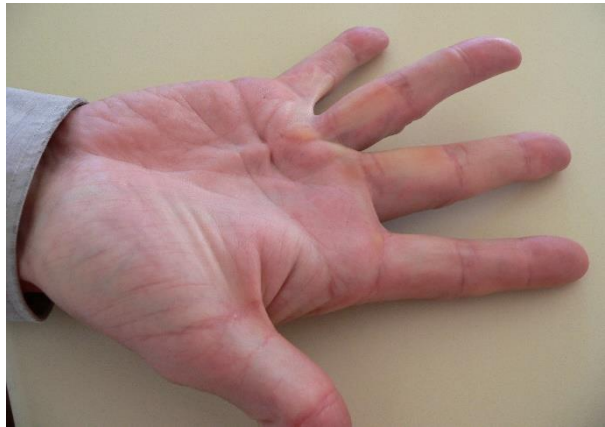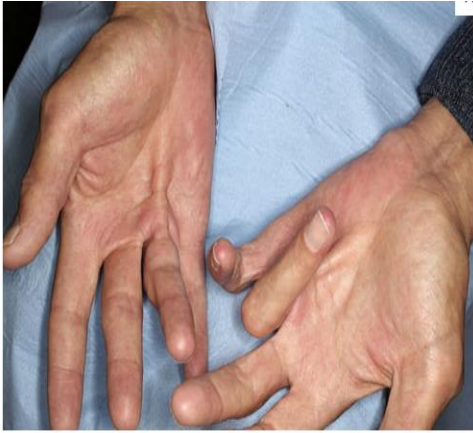❓ Clubbing .



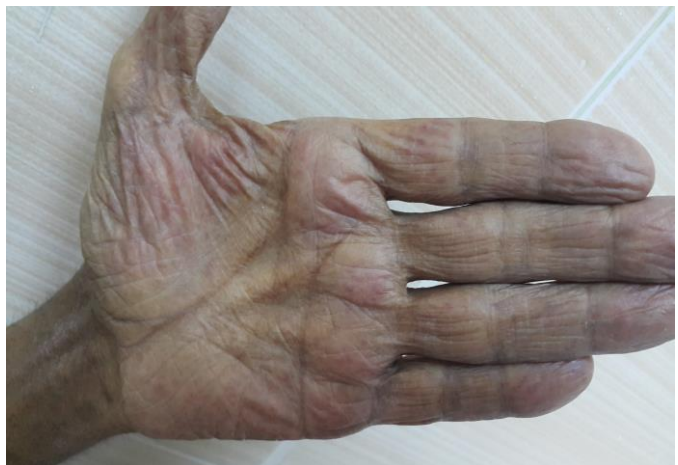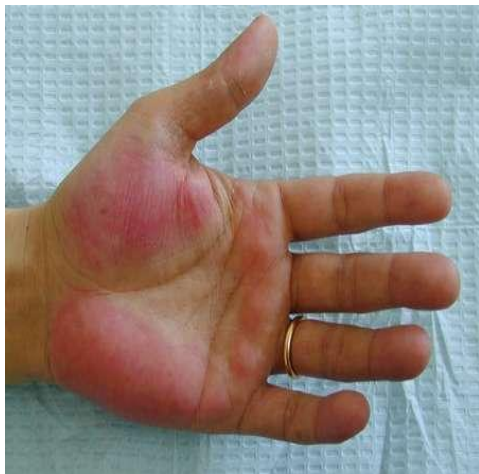❓ Leuconychia = white nails(in hypoalbuminaemia).



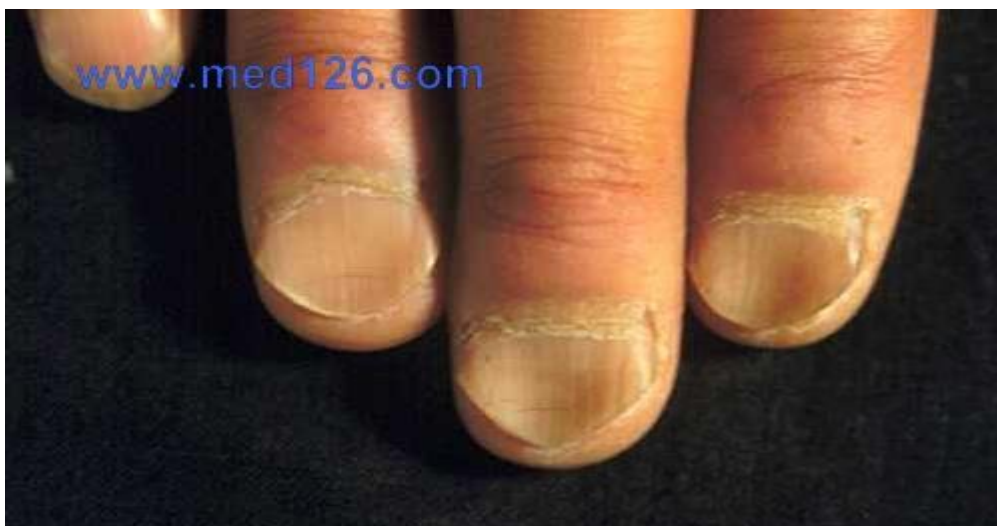❑ Dupuytren's contracture



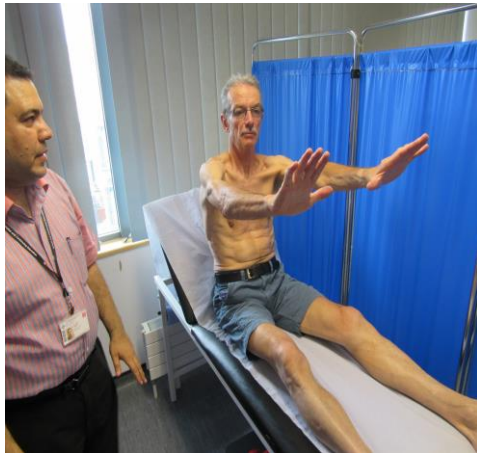❑ Palmar Erythema



❑ Koilonychia = spooning of nails(iron deficiency).

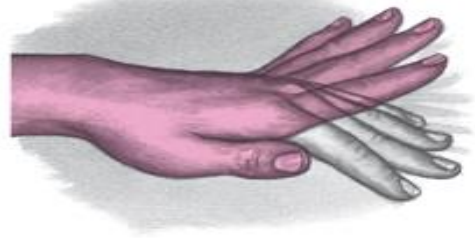

☒ Liver Flap .

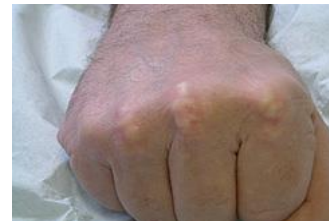

Recognizing asterixis

In asterixis, the patient's wrists and fingers are observed to "flap" because of a brief, rapid relaxation of wrist dorsiflexion.



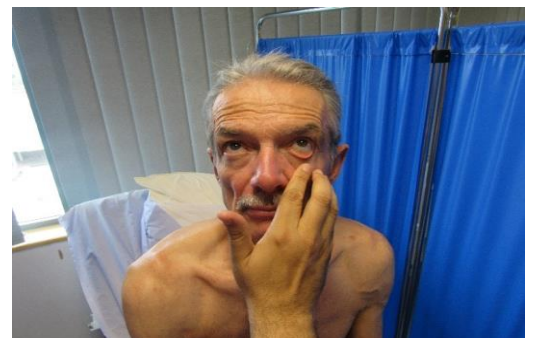
☒ Tendon Xanthoma (Yellowish Discoloration Of Tendon At Wrist) : Hyperlipidemia .



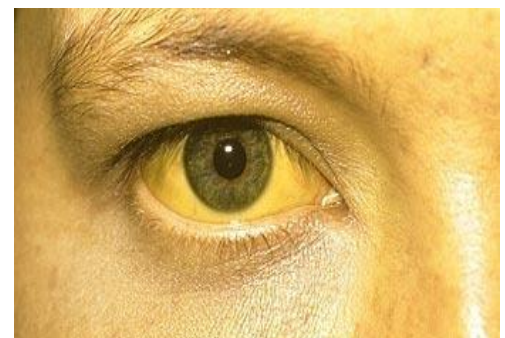Examination of Head & Neck :

☒ Eye :

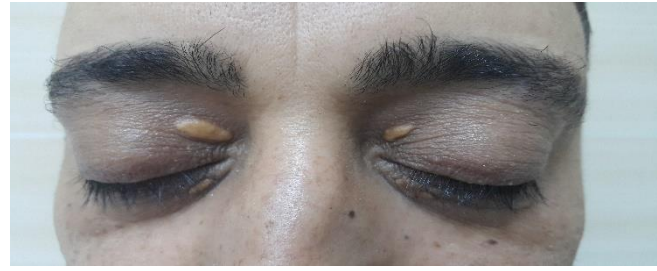- Pallor : Anemia



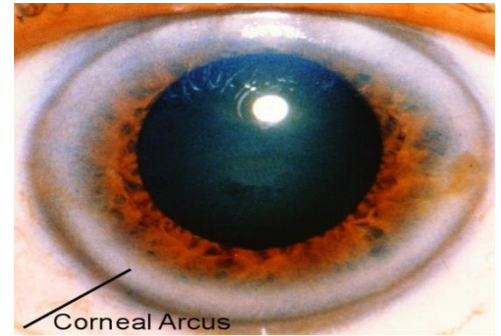
- Jaundice



Xanthelasma : Hyperlipidemia .



Corneal Arcus:



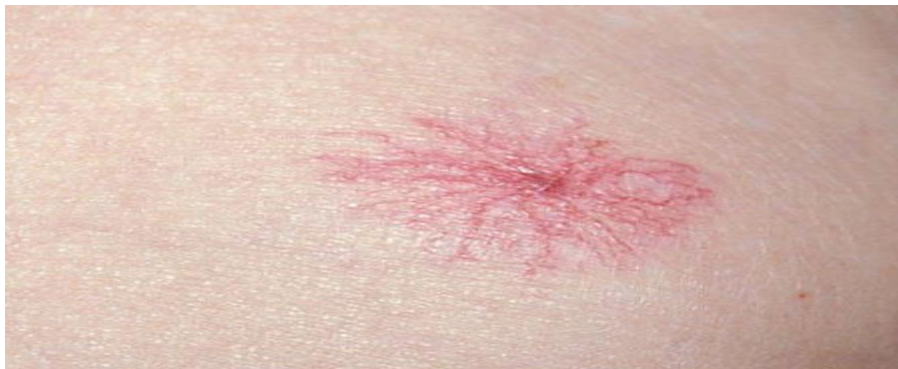Neck :

- Lymph Nodes (See respiratory system examination).

Chest:

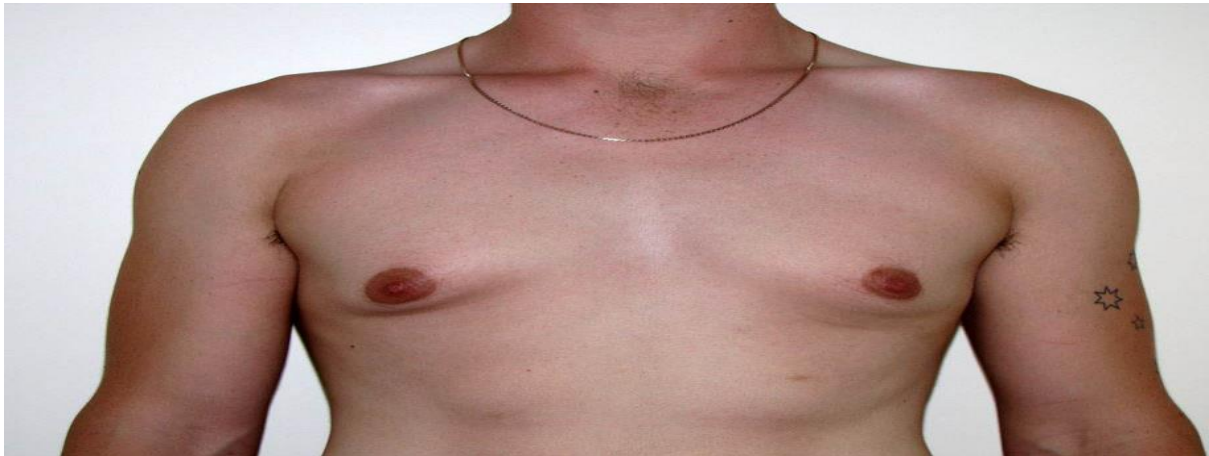Spider naevi

In distribution of SVC . It fades if you compress the central arteriole (in liver cell failure)



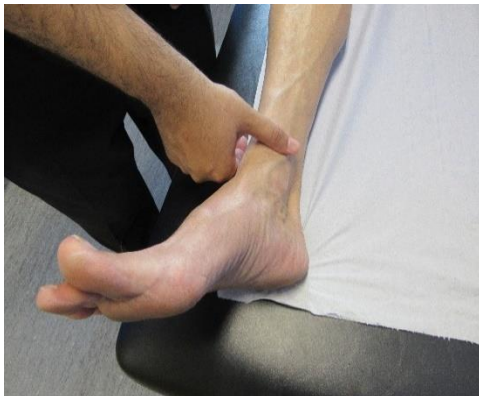Male gynaecomastia

Enlarged breast in male with tender retroareolar disk.(liver disease)

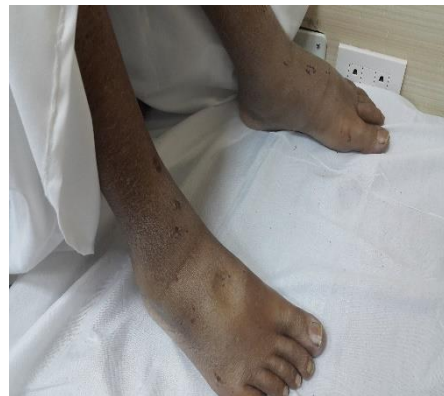

Examination of the Lower Limb

- Skin Changes , Muscle Wasting , Loss Of Hair .
- **Oedema** : Pitting / Non-Pitting - Unilateral / Bilateral - Level .

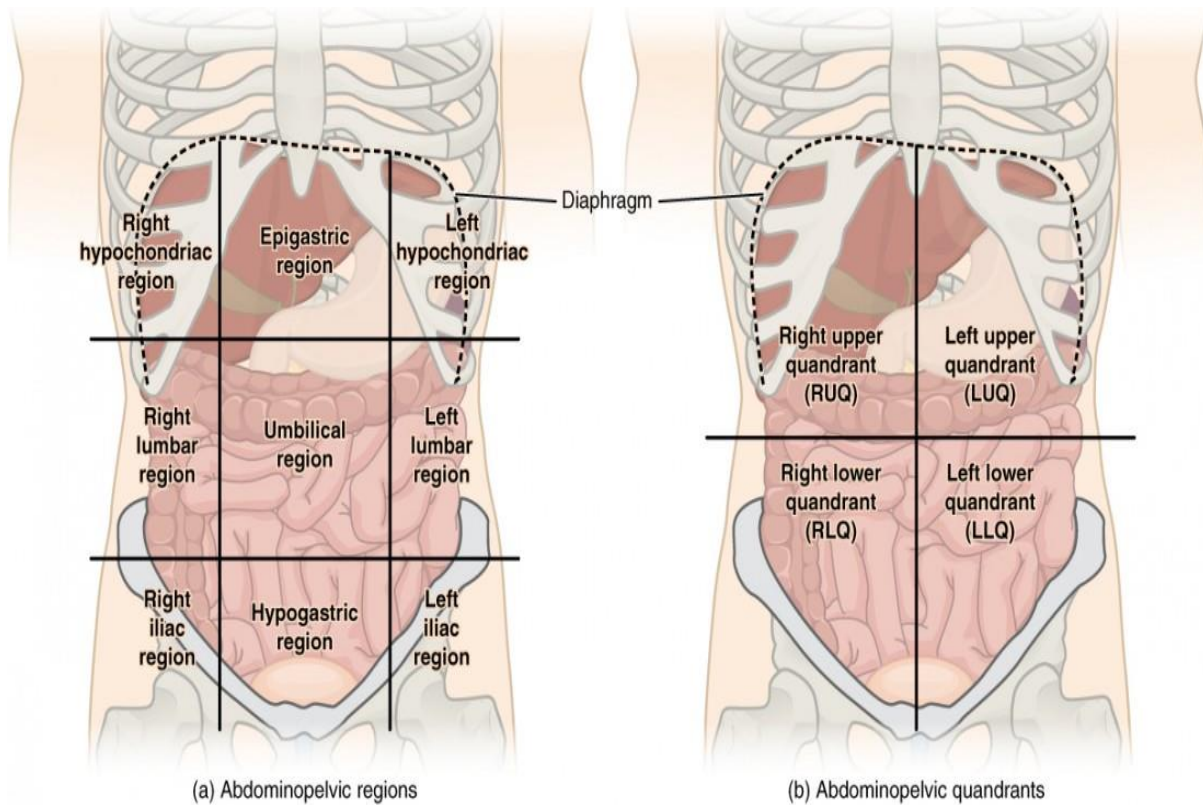


Check Lower limb oedema



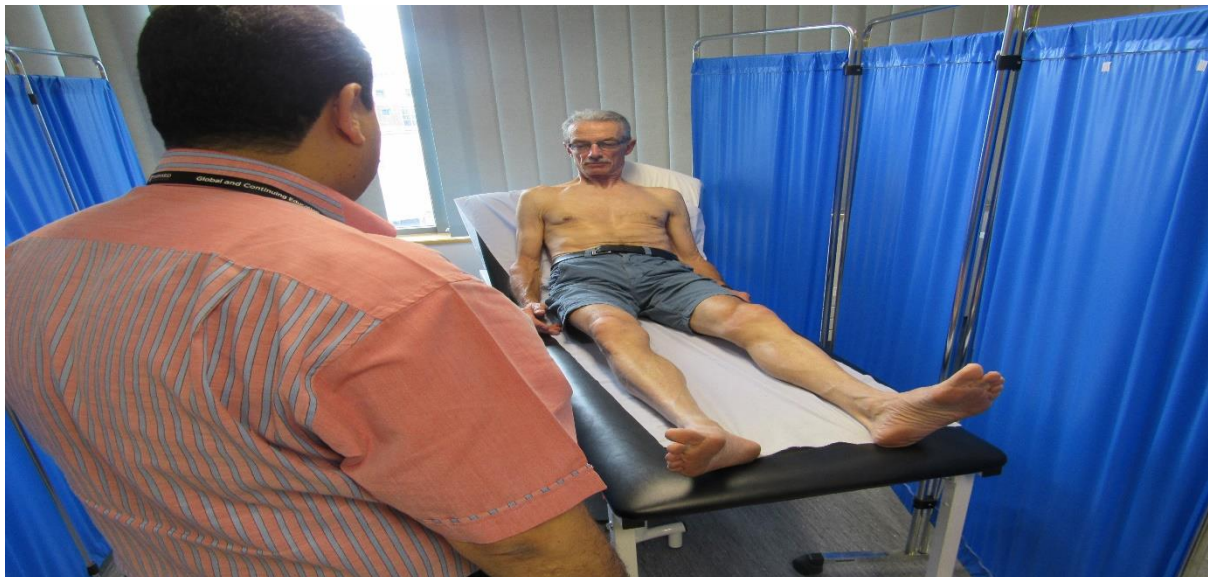Pitting oedema

Local Abdominal Examination : Compartments of the abdomen

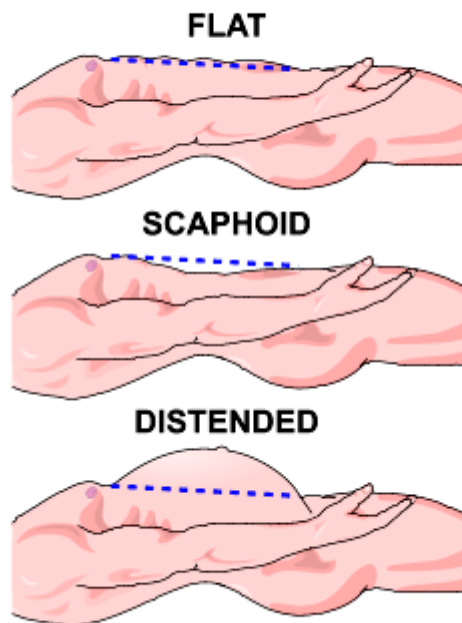


Inspection

Observe the patient from the end of the bed



1. Abdominal Contour : bulge (Ascites , pregnancy , obesity, distension)or retraction(scaphoid abdomen in starvation and malignancy)

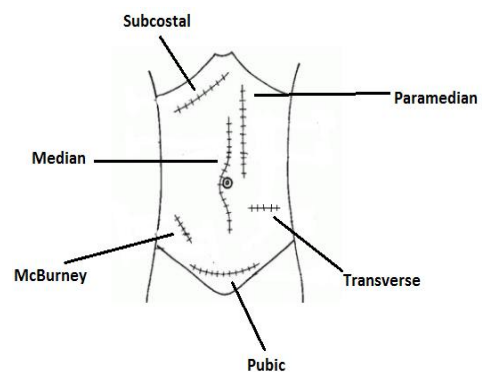
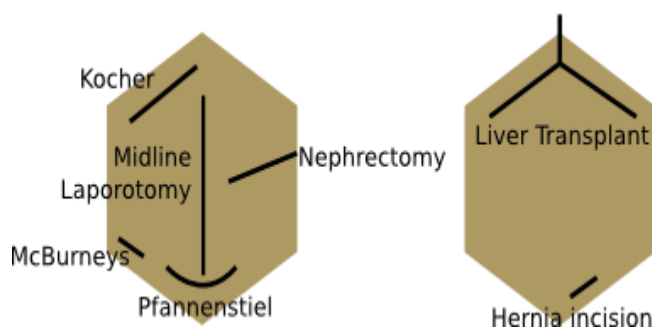


2. Movements with respiration

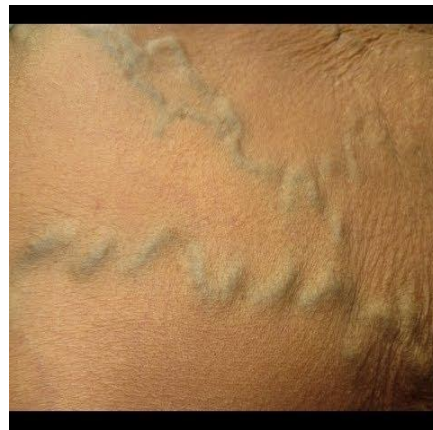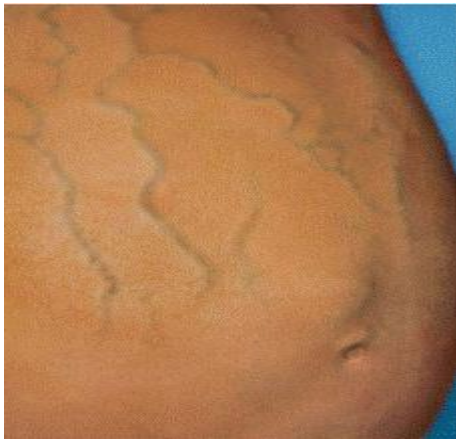Males : Abdomino-Thoracic

Females : Thoraco-Abdominal

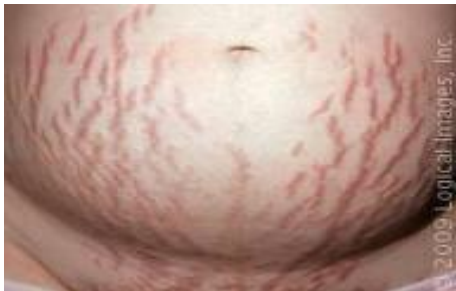3. Previous Scars :



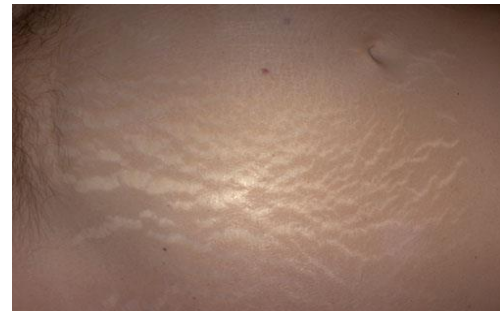4- Dilated Veins



5- Abdominal Striae:



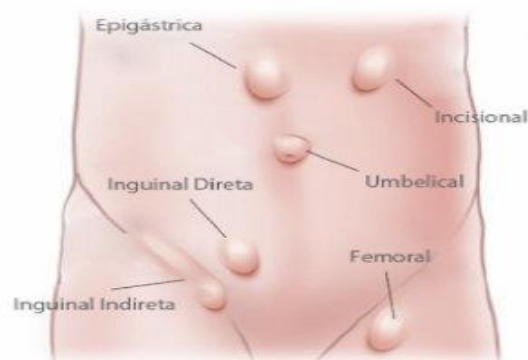
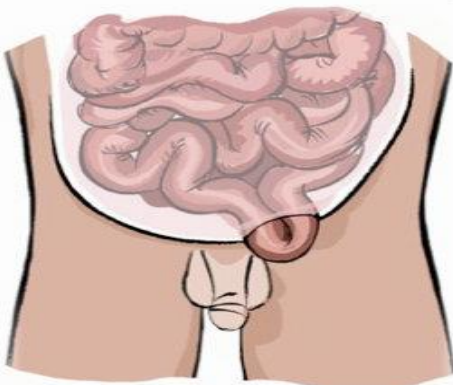
Stria Rubra



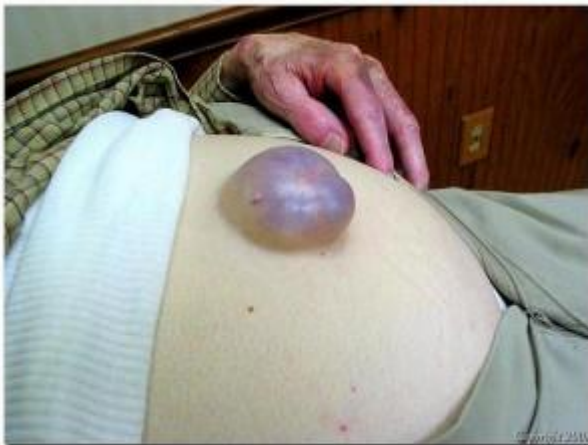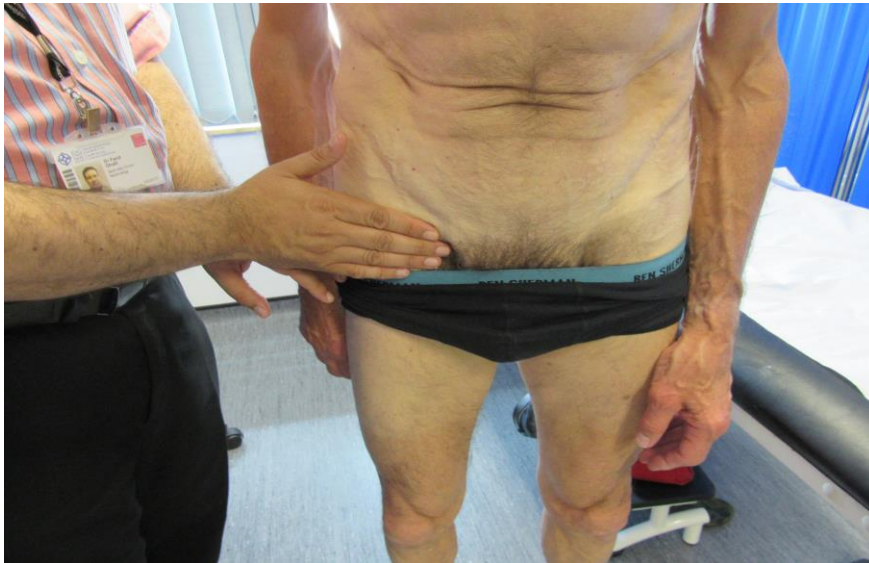Stria Alba

6- Hernias:

Different Types Of Hernias

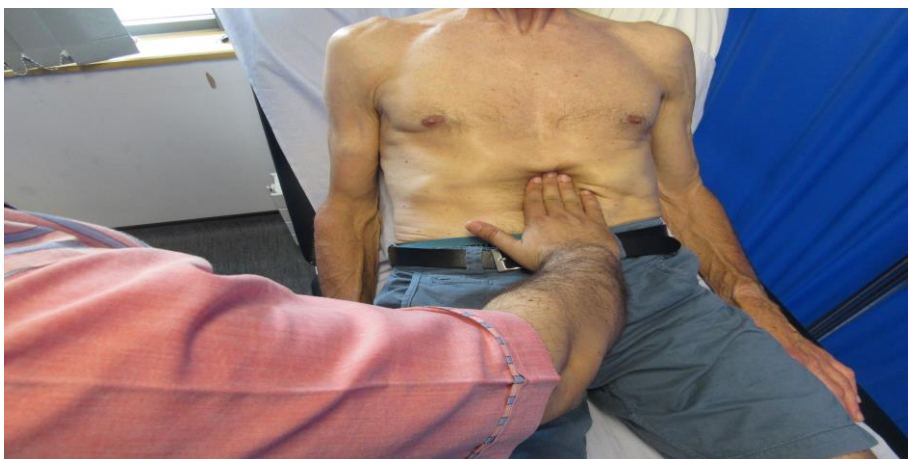

Examination of Hernia may need patient to stand up and cough to see the hernia

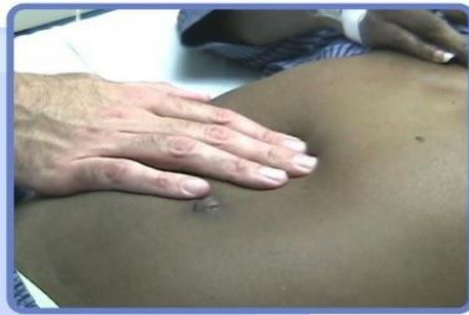

Umbilical hernia in a cirrhotic patient

7. Any Visible Pulsations : Determine The Site .

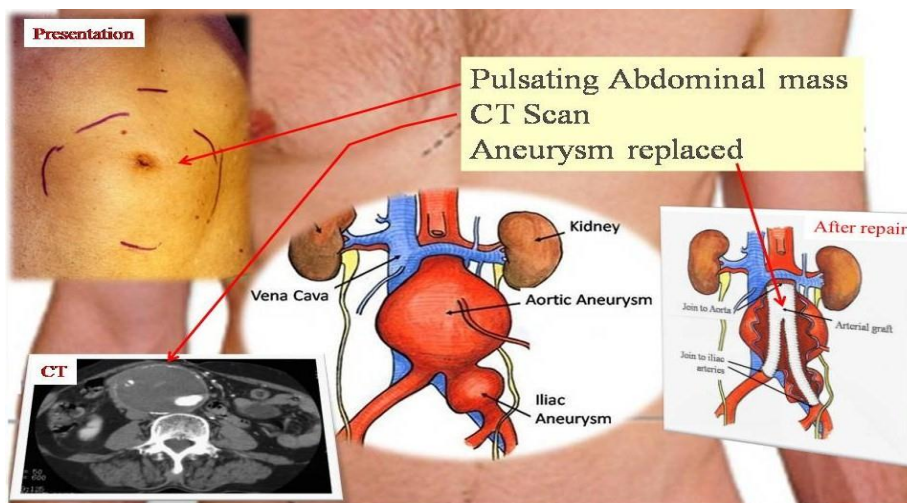


- Epigastric Pulsations :
Source : either
Right Ventricle ,
Aorta Or Left
lobe of the liver (Differentiate by palpation) .

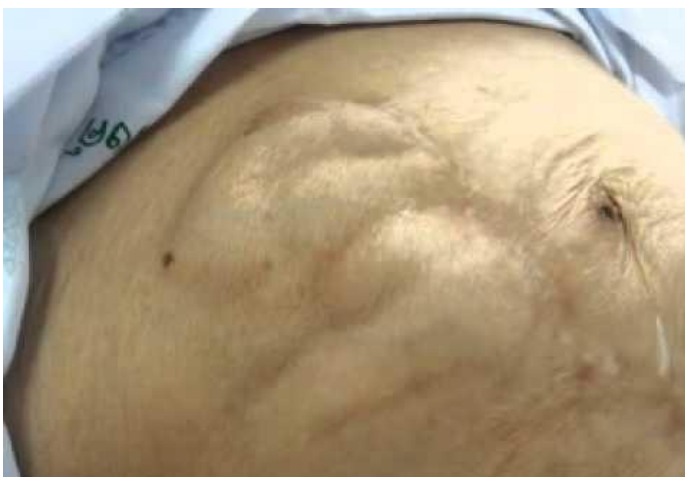

Pulsatile Liver

Pulsation transmitted from aorta Tricuspid valve insufficiency



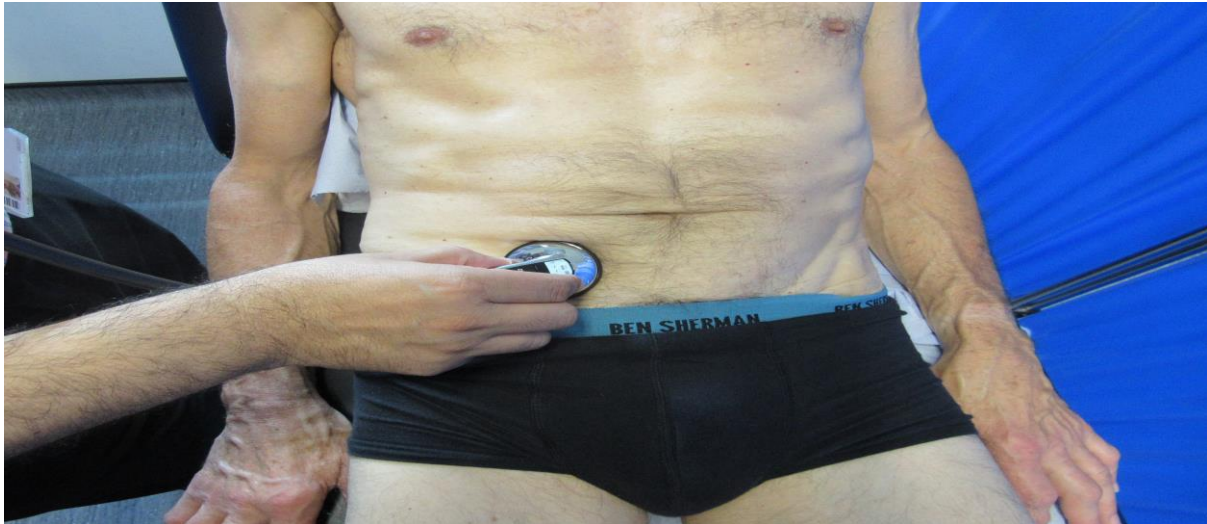8- Any visible Peristalsis:



Auscultation:

Bowel sounds are 'gurgles' that are heard normally every 5-10 seconds. Listen for up to 2 minutes before concluding that bowel sounds are absent (peritonitis, paralytic ileus). In intestinal obstruction bowel sounds are sometimes described as tinkling.

PS: *Unlike other examinations, auscultation for bowel sounds may be carried out before percussion and palpation due to adverse effect that these procedures may have on the sound from the bowels.*



Other Auscultatory findings:

- 1- **Venous Hum:** over right upper quadrant due to portosystemic collaterals in portal hypertension
- 2- **Splenic friction rub:** over the spleen (left upper quadrant) 10th rib in inflammation of peritoneal coverage of the spleen (e.g. splenic infarction) .
- 3- **Aortic Bruit:** over abdominal aorta in case of aneurysm.
- 4- **Renal artery bruit:** over renal artery in case of renal artery stenosis.

Palpation:

" Don't Forget To Warm Your Hand "

I. Superficial Palpation:

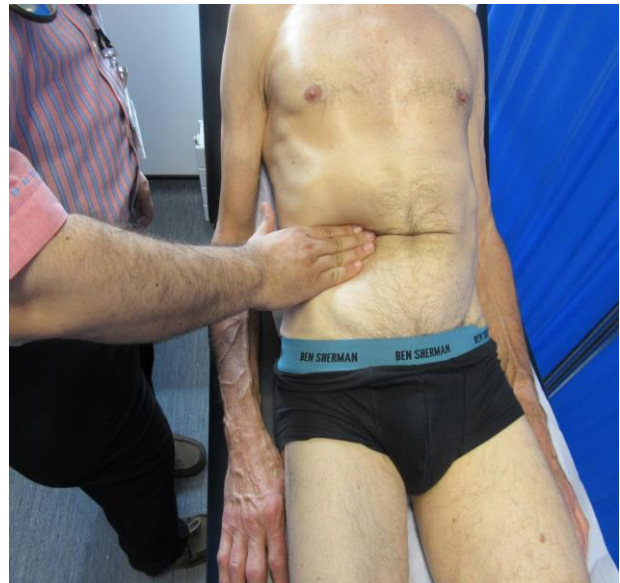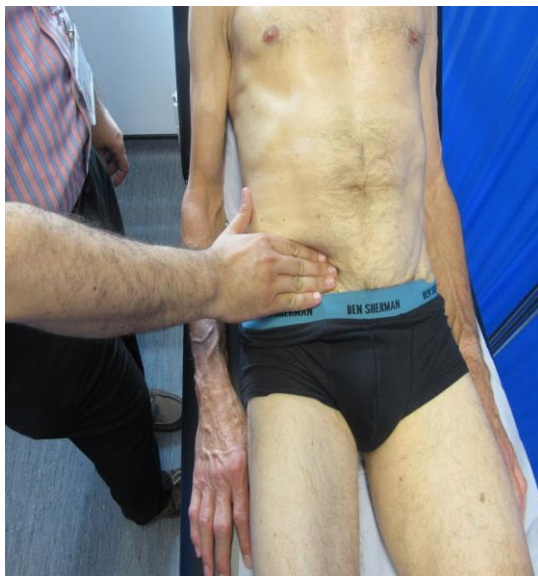- 1- check if any pain and start away from that area, aim to be close to the patient's level,
- 2-Observe patient's face for pain during the exam
- 3- Start gently/softly palpating the abdomen - thinking of there being 9 regions/areas –
- 4- check for tenderness, guarding, masses, rebound tenderness – guarding is a sense that the abdominal muscles are tensing as you press to 'protect' a tender area; rebound tenderness is pain experienced by the pain when, after pressing down on part of the abdomen you release the pressure – and usually indicates intra-abdominal pathology.

II. Deep Palpation:

1- Palpate the liver .

Draw an imaginary outline of the liver on the patient's abdomen – the normal liver may be just palpable below the costal margin – the liver enlarges towards the right iliac fossa and moves down as the patient takes a breath in.

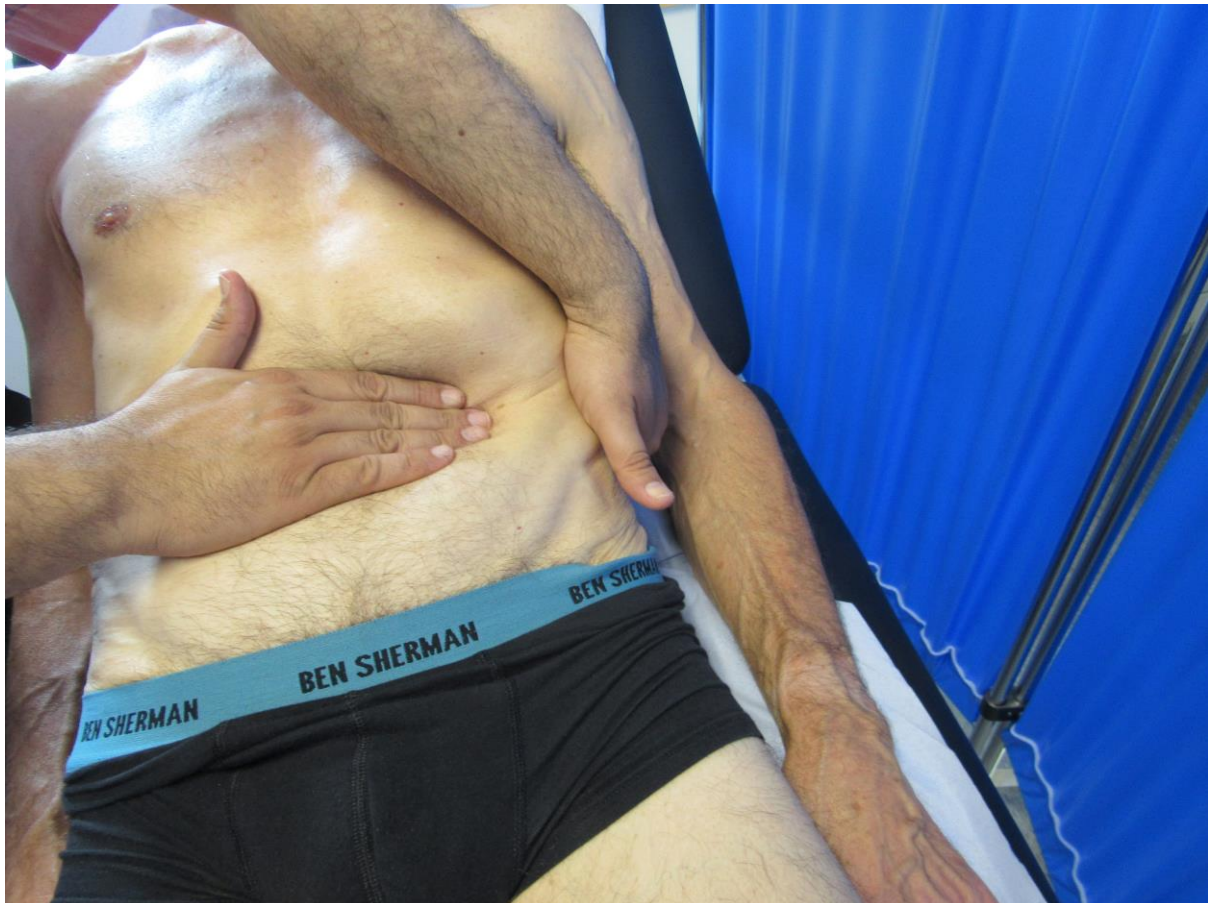So – the technique is to **start moderately deep palpation in the right iliac fossa and gradually work upwards towards the costal margin**. Position your hand either with your finger tips pointing upwards towards the costal margin or across the abdomen at right angles to the rectus sheath. Position your hand and ask the patient to breath in – an enlarged liver will descend and push against your fingers. If you feel nothing move your hand one cm towards the costal margin and repeat, and so on until you either reach the costal margin or feel the liver edge.



2. Palpate the spleen :

The normal spleen is not palpable since it is underneath the left costal margin. When it is enlarged the spleen enlarges towards the umbilicus and – in gross enlargement – towards the right iliac fossa. The spleen also moves down with breathing in.

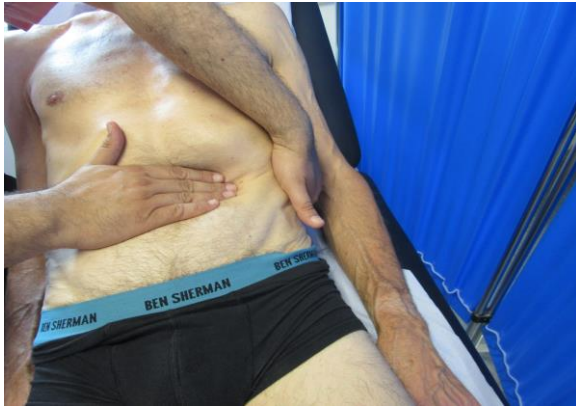So – start from the right iliac fossa/umbilicus with moderately deep palpation. Ask the patient to breath in – an enlarged spleen will push against your fingers. Move your hand progressively (1 cm at a time) towards the left costal margin.



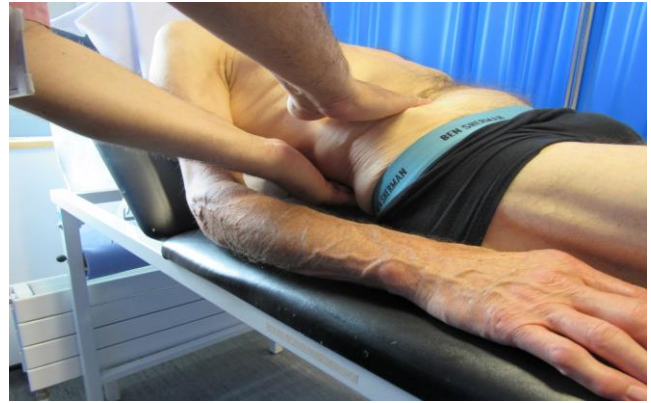Bimanual splenic examination : as in picture , if spleen is not palpable by normal palpation starting from right iliac fossa as above

3. Palpate the kidney

In gross enlargement the kidney may be felt during routine palpation of the abdomen. As it is a retroperitoneal organ, to feel lesser degrees of enlargement needs a particular technique. Place your left hand behind the patient, below the ribs and 'push' the kidney upwards. With your right hand, palpate the abdomen as the patient breathes out. An enlarged kidney is felt as a mass between your two hands.



Left kidney

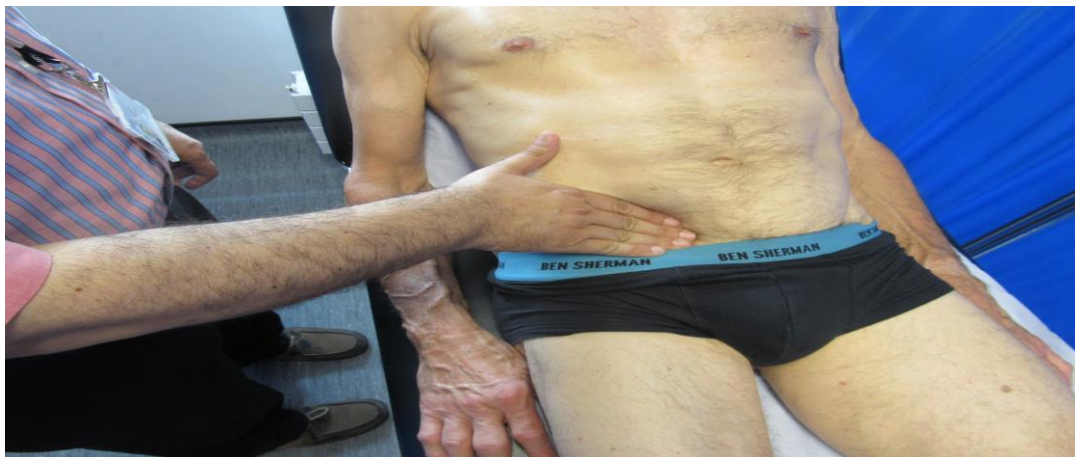

Right Kidney

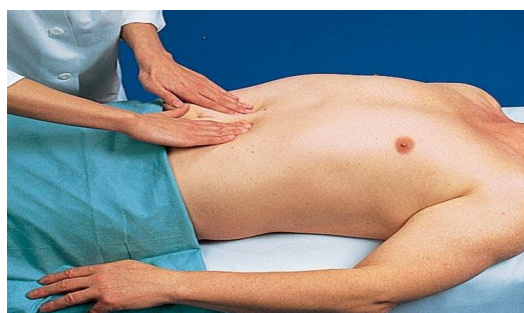Difference between kidney and splenic swellings

<i>➤ SPLEEN</i>	<i>➤ KIDNEY</i>
<i>➤ Finger insinuation between swelling and costal margin not possible</i>	<i>➤ Possible to push fingers between kidney swelling and costal margin</i>
<i>➤ Splenic notch may be palpated</i>	<i>➤ No notch</i>
<i>➤ Moves freely with respiration, direction of movement is down and to right</i>	<i>➤ Moves with respiration but much less readily, direction of movement is vertically down</i>
<i>➤ Renal angle resonant</i>	<i>➤ Renal angle (angle between 12th rib and lateral margin of erector spinae muscle) may become dull</i>

4. Palpate the bladder :



5- Palpate the Aorta

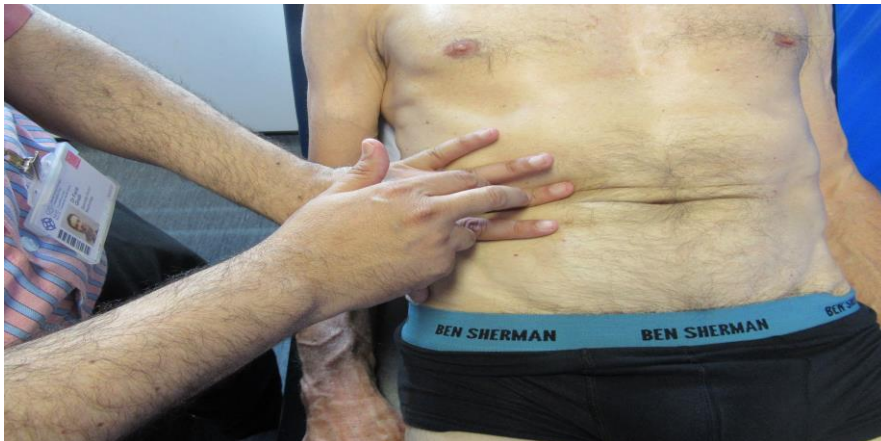

Percussion

Since the abdomen is usually full of airfilled organs (the bowels) it is normally resonant to percussion apart from the liver and the spleen.

1- Lower border of the liver:

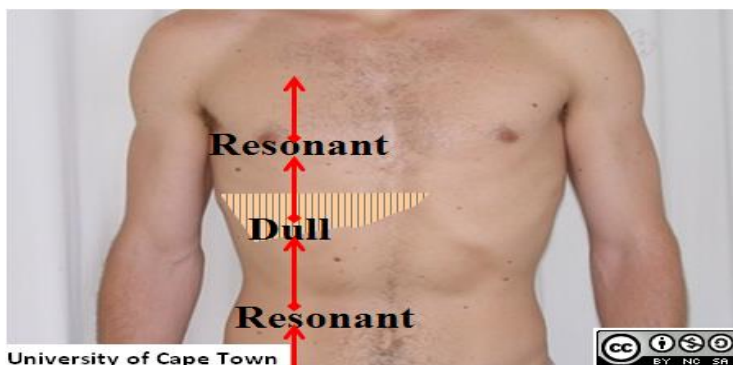
Start percussion from right iliac fossa and go upwards in mid clavicular line till you reach the area of lower border hepatic dullness .

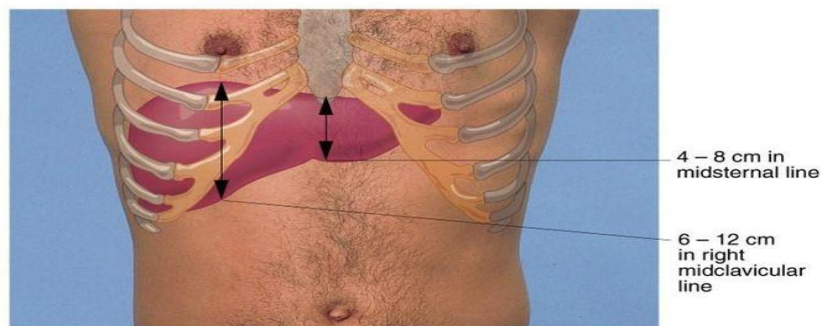


2- Upper Border of the liver:

Start from the second right intercostal space till you reach the hepatic dullness which is normally in 5th right intercostal space

Percuss downwards from the fifth intercostal space as a check of the size of the liver AND localize the right lobe lower edge by palpation (**liver span**). **Normal liver span is 6-12 cm at the right MCL and 4-8 cm at midaternal line. Measurements by means of percussion typically underestimates liver size.**

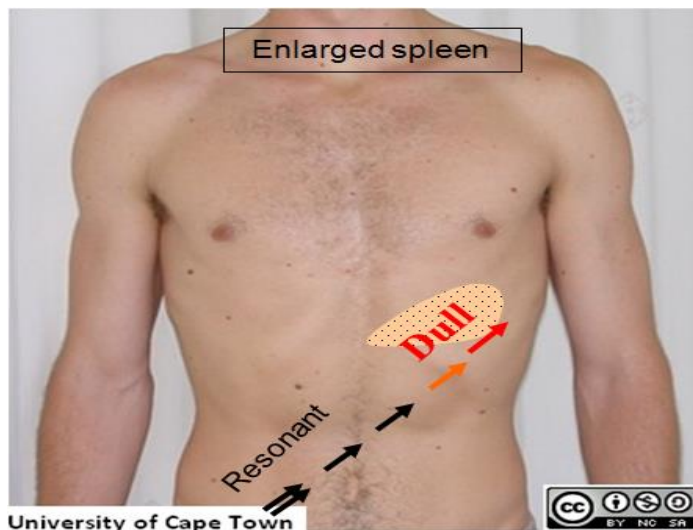




Normal liver spans

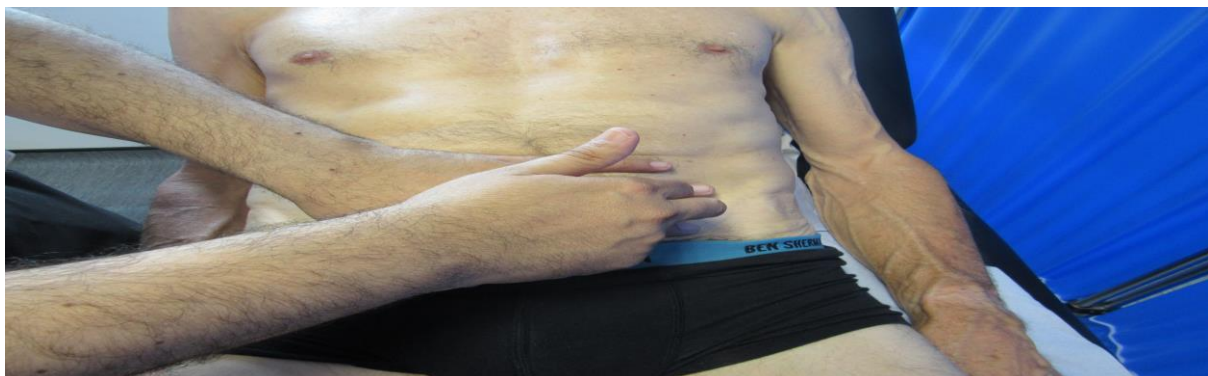Copyright © 2003 by Lippincott Williams & Wilkins. Instructor's Resource CD-ROM to Accompany Bates' Guide To Physical Examination And History Taking, 8th edition

2- Percussion of the spleen:



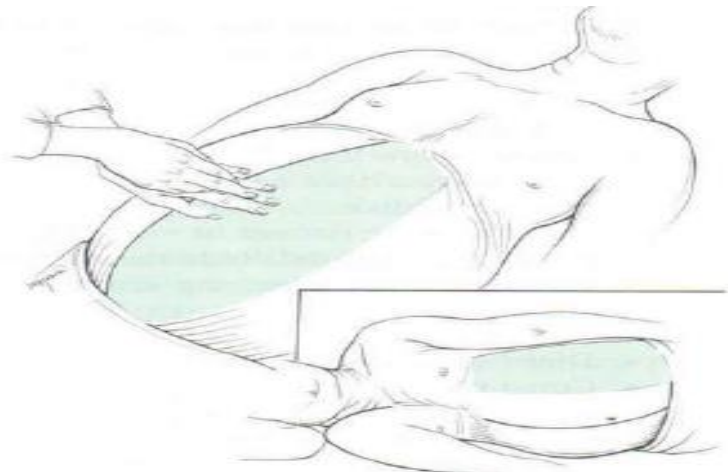
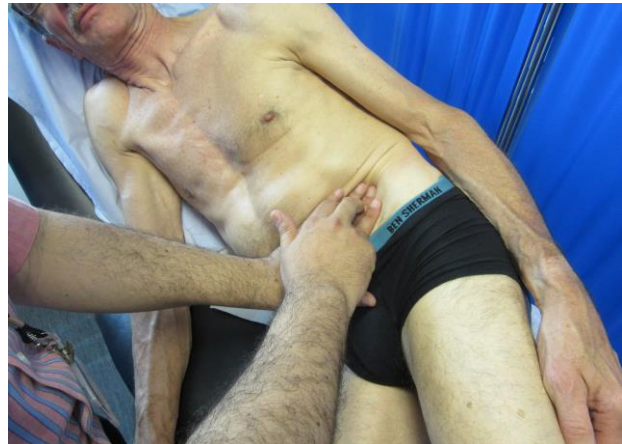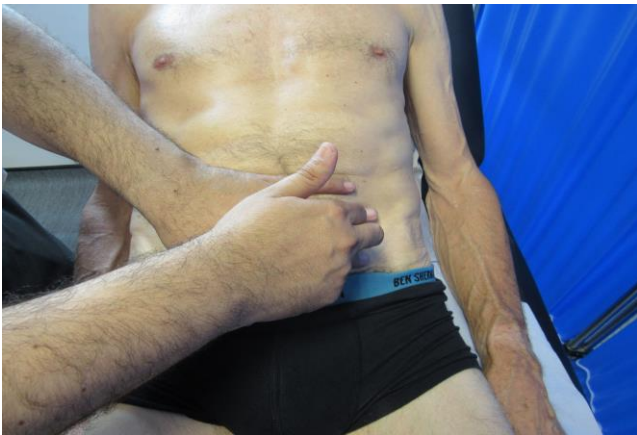3- Percussion of Bladder:

An enlarged bladder may be felt and percussed rising up centrally from the pelvis.



4- Shifting Dullness:

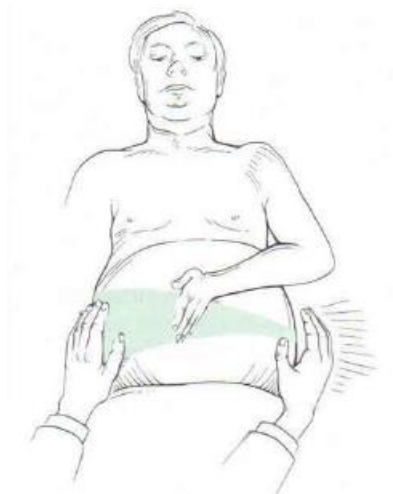If there is free fluid in the abdomen – ascites – it may be appropriate to test for ‘shifting dullness’. With the patient flat on their back, percuss from the umbilicus out to the flanks on each side and note where the tone becomes dull. Then ask the patient to lie on one side for about 15 secs and repeat the exercise. If there is free fluid the dullness on the flank which is now upper most should have shifted (as the fluid moves down) and this area should now be resonant.



Testing for shifting dullness. *Shaded areas* represent areas where dullness transitions to tympany. Note the shift to dependent areas in accordance with changes in patient position. (From Swartz M. *Textbook of Physical Diagnosis: History and Examination*. 6th ed. Philadelphia: Saunders; 2010 [p. 497, Figure 17-18].)

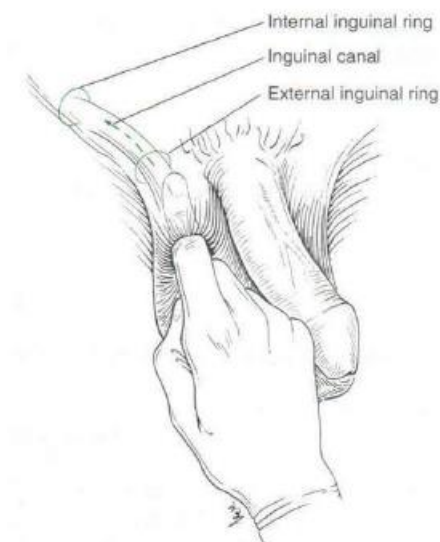
5-Fluid Thrill

If there is gross ascites, it may be possible to feel for a ‘thrill’ – vibration sensation. Ask the patient to place their hand on the midline of the abdomen. Flick one side of the abdomen and place your other hand on the other side of the abdomen to feel if this creates a vibration.

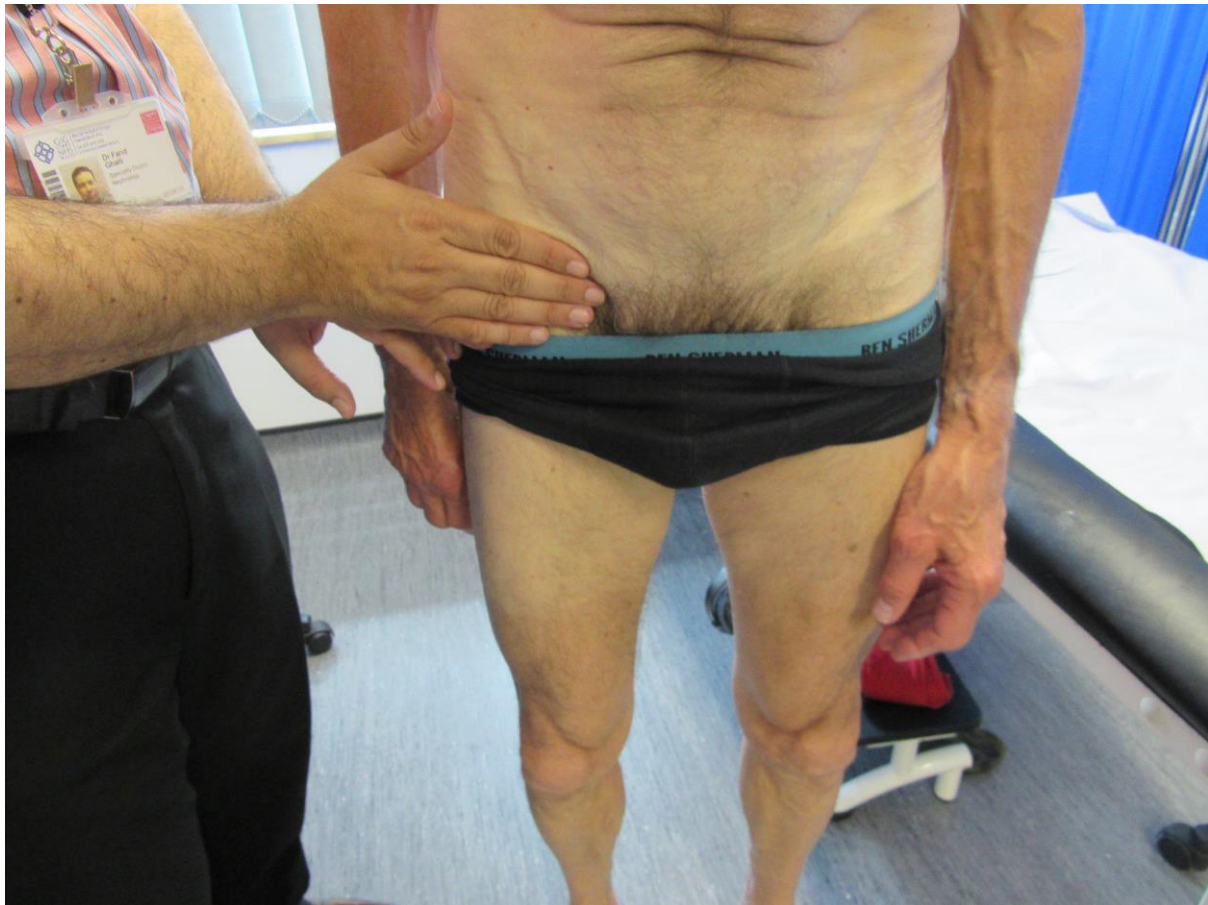

Testing for a fluid wave. (From Swartz M. *Textbook of Physical Diagnosis: History and Examination*. 6th ed. Philadelphia: Saunders; 2010 [p. 497, Figure 17-19].)

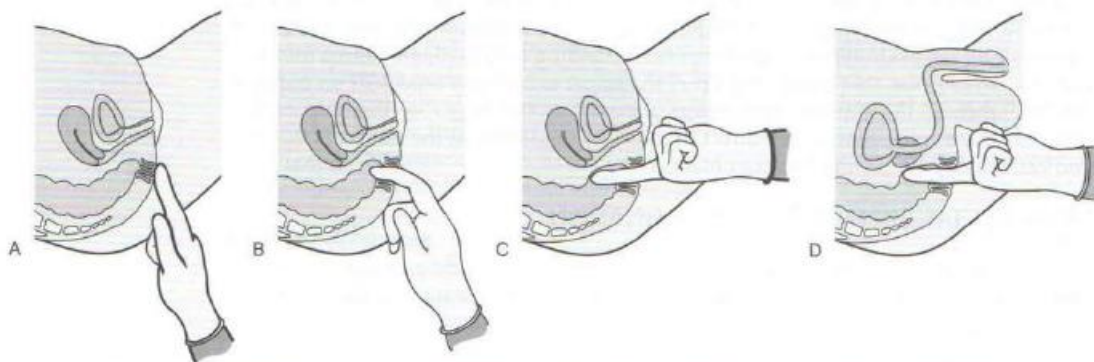
Hernia Examination



Examination for inguinal hernia. (From Swartz M. *Textbook of Physical Diagnosis: History and Examination*. 6th ed. Philadelphia: Saunders; 2010 [p. 539, Figure 18-33].)

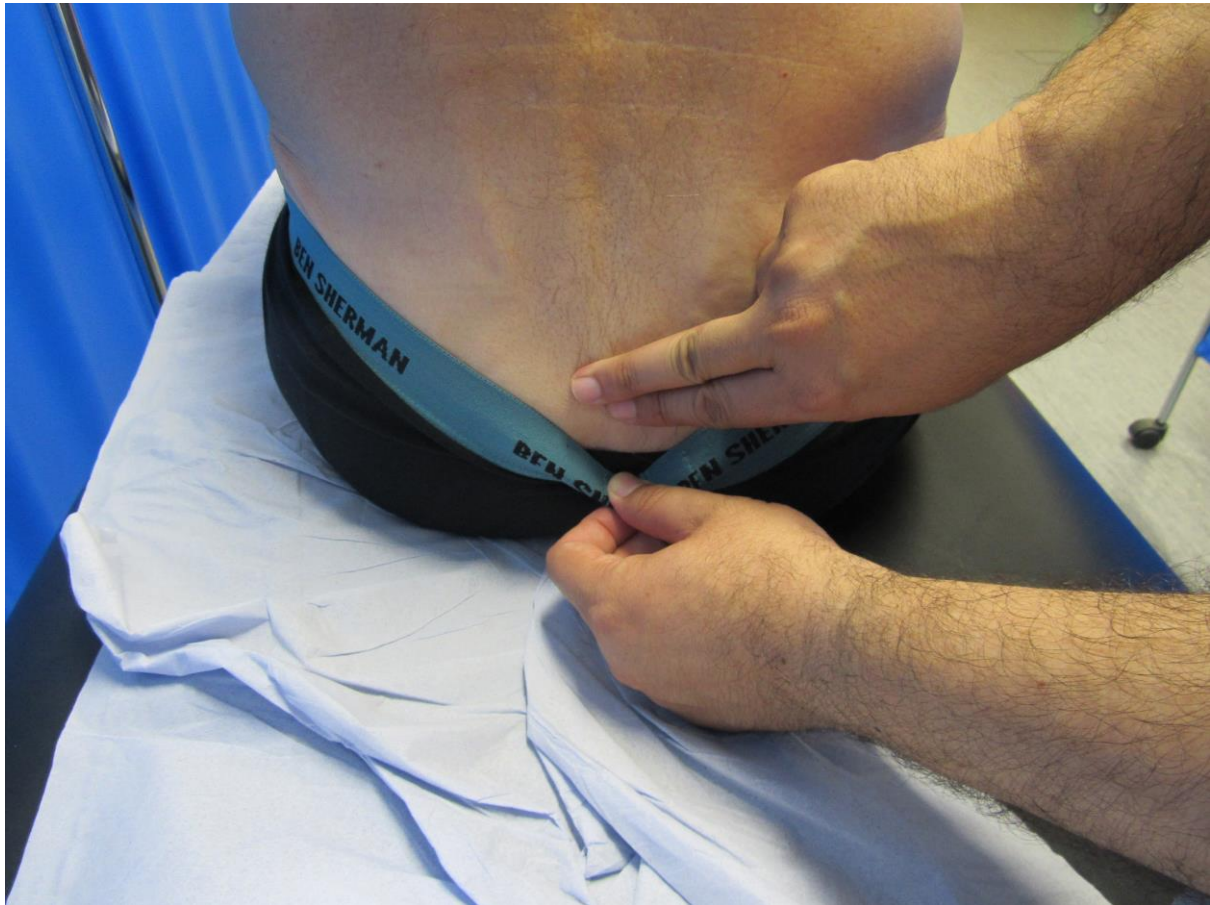

Rectal Examination



Technique for digital rectal examination. **A**, Applying pressure to the rectum. **B**, Insertion of examiner's finger into patient's rectum. **C**, Anatomic considerations for rectal examination in a woman. **D**, Anatomic considerations for rectal examination in a man. (From Munro JF, Campbell IW, eds. *Macleod's Clinical Examination*. 10th ed. Edinburgh: Churchill Livingstone; 2000 [p. 175, Figure 5.22].)

PS : Do not forget to check sacral oedema



References :

- 1- OSCE And Clinical skills handbook: Hurley KF, second edition.Elsevier Canada 2011
- 2- Online osceskills website. www.osceskills.com
- 3- Macleod's clinical examination ,thirteenth ed. 2013
- 4- www.geekymedics.com
- 5- Google images